

Notoedric Mange Associated With *Malassezia* in Cats

Case Study

B.Sudhakara Reddy^{1*}, S.Sivajothi²¹ Assistant Professor (Veterinary Medicine), Teaching Veterinary Clinical Complex, Sri Venkateswara Veterinary University, Proddatur, Y.S.R.District, Andhra Pradesh, India.² Assistant Professor, Dept. of Veterinary Parasitology, Sri Venkateswara Veterinary University, Proddatur, Y.S.R.District, Andhra Pradesh, India.

Abstract

Notoedres cati associated with *Malassezia* was observed in a domestic cat. Cat exhibited crust formation, hyperkeratosis, alopecia, intense pruritus and seborrhoea over the ears, face, neck and ventral abdomen regions. Laboratory examination of samples revealed *Notoedres cati* mites in skin scrapings and *Malassezia* organisms in tape impression smears. Cat was treated with weekly thrice oral ivermectin @ 300 µg/kg body weight, supportive therapy and weekly twice bathing was advised with shampoo containing 2% miconazole and 2% chlorhexidine. Complete clinical recovery along with absence of mites in skin scrapings and absence of *Malassezia* organisms in impression smears were noticed after completion of six doses of oral ivermectin along with supportive therapy.

Key Words: *Notoedres cati*; *Malassezia*; Cat; Ivermectin

*Corresponding Author:

B.Sudhakara Reddy,
Assistant Professor (Veterinary Medicine),
Teaching Veterinary Clinical Complex,
Sri Venkateswara Veterinary University,
Proddatur, Y.S.R.District, Andhra Pradesh, India.
E-mail: bhavanamvet@gmail.com

Received: February 22, 2014

Accepted: March 21, 2014

Published: March 24, 2014

Citation: B.Sudhakara Reddy, S.Sivajothi. (2014). Notoedric Mange Associated With *Malassezia* in Cats, Int J Vet Health Sci Res, 02(01), 18-20.
doi: <http://dx.doi.org/10.19070/2332-2748-140005>

Copyright: B.Sudhakara Reddy © 2014. This is an open-access article distributed under the terms of the Creative Commons Attribution License, which permits unrestricted use, distribution and reproduction in any medium, provided the original author and source are credited.

Introduction

Notoedric mange is highly contagious disease of cats and it is caused by *Notoedres cati* mites and it can be opportunistically infest other animals [1]. *Malassezia* yeasts are belongs to normal cutaneous or mucosal microbial of many warm-blooded vertebrates. These yeasts are recognized as opportunistic pathogens that play a significant role in the development of different human and animal diseases such as otitis externa or seborrheic dermatitis. *Malassezia* yeasts can also be isolated from the external ear canal and mucosae of healthy cats as well as cats with otitis externa and dermatitis. In healthy cats, reported percentages of isolation of *Malassezia* yeasts ranges from less than 10% to approximately 20% and up to 40% [2]. *Malassezia* species are frequently isolated from younger cat's age of 1 to 4 years [3]. The present report describes the rare

clinical condition i.e. Notoedric mange associated with *Malassezia dermatitis* in a domestic cat and its successful management.

Case History and Observations

A six months old tom cat was presented to the Teaching Veterinary Clinical Complex, Proddatur with a history of seborrhoea and chronic intense pruritus as a chief complaint. Up on clinical examination cat had scales, erythema, greasiness, alopecia, malodorous discharge from lesions and hyperpigmentation. Distribution of the lesions was noticed over the face, ears, neck and ventral abdomen (Fig.1). Skin scrapings and tape impression smears were collected from the skin lesions at various sites for laboratory examination. Microscopic examination of scrapings revealed the presence of ova and adult live mites. Skin scrapings were also digested in 10 % NaOH solution and examined microscopically for morphology, which revealed a round body, short legs, and long unjointed stalk with a sucker shorter limb stalks and a dorsal anus (Fig.2). Based on the morphology, mites isolated from the cat were identified as *Notoedres cati* [4]. Microscopic examination (100X) of methylene blue stained tape impression smears revealed presence of the *Malassezia* organisms 4-6/ field from the samples of ears and 2-3/field from the samples of face, ventral abdomen and dorsum regions (Fig.3). No other parasites and fungal spores were noticed in the clinical samples.

Treatment and Discussion

Based on the clinical signs and laboratory examination of samples the condition was confirmed as Notoedric mange associated with *Malassezia dermatitis*. Treatment was started with weekly thrice oral administration of ivermectin @ 300 µg/kg body weight for six doses along with supportive therapy by oral administration of 2 ml of multi-vitamin and mineral syrup (Zincovit) daily. To control

Figure 1: Skin lesions over the body in a cat

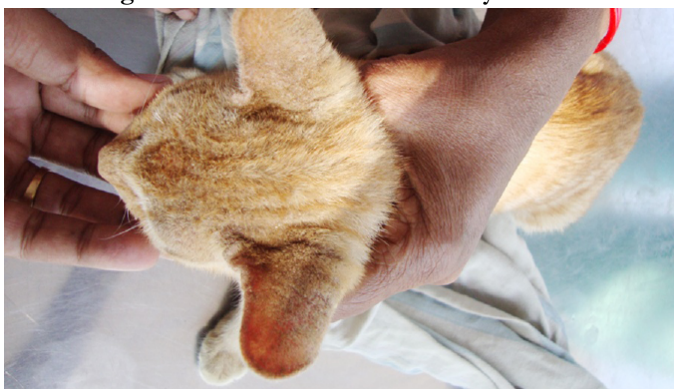

Figure 2: Adult Notoedric cati mites in skin scrapings (40X)

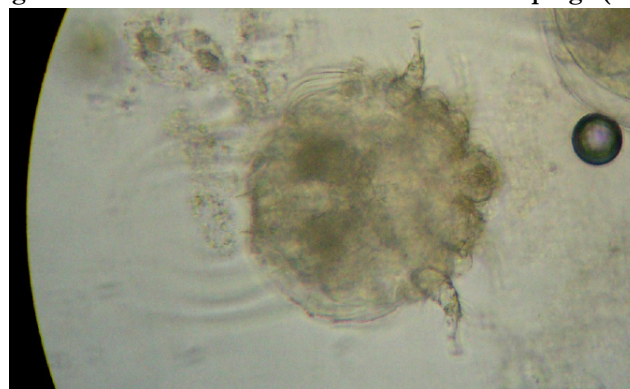
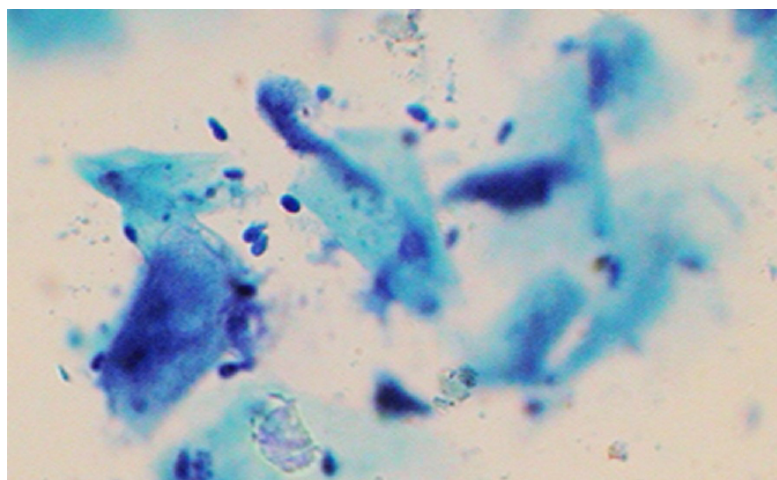


Figure 3: Malassezia in tape impression smears (100X)



Malassezia overgrowth bathing was advised with shampoo containing 2% miconazole 2% chlorhexidine (micodine) weekly twice for 4 weeks. Significant clinical improvement was noticed after one month of therapy. Efficacy of the drug was assessed based on the clinical recovery and examination of skin scrapings and tape impression smears at weekly intervals of post therapy.

Post treatment clinical examination of cat on 7th day revealed partial improvement in pruritus and disappearance of scales. Laboratory examination of scrapings revealed dead mites and the presence of *Malassezia* organisms in tape impression smears collected from the face region. By 14th day cat was totally free from pruritus and alopecia. Scrapings were negative for mites and presence of *Malassezia* organisms in tape impression smears was noticed. Oral ivermectin was continued for two more weeks along with supportive therapy and external application of micodin shampoo to treat unnoticed mites. On 28th day of examination, cats were free from all lesions and hair growth was also observed. Microscopic examination of scrapings and impression smears did not reveal any significant abnormalities. Senthil Kumar observed the higher efficacy of parenteral ivermectin @ 200 µg/kg body weight, S/C in cats with Notoedric cati infestation [5]. No adverse clinical reactions were observed after the treatment with oral ivermectin and bathing with micodine shampoo.

In the present study the cat had skin lesions covering the face, neck and ventral region of body. The characteristic itching and hair loss pattern was often all that was needed to diagnose the *Notoedric* mange in the cat [6]. *Malassezia spp* are commensal yeast of skin and mucosa and result in generalized as well as local skin

disease in all breeds of cats worldwide [7]. In most cases *Malassezia spp* infection is a secondary problem. It can occur in conjunction with allergies, immune mediated disease, chronic bacterial infections, long-term antibiotic use and seborrhea [3]. Localised infections are more common and 95% of cats with otitis externa have *Malassezia* infection, either as a primary etiological agent, or secondary to other causes [8]. In the present case, based on the history and development of skin lesions over the body cat was initially affected with mite infestation. Mite induced allergy is responsible for severe itching which may leads to favorable environment conditions for proliferation of *Malassezia* over the skin. Sivajothi *et al.* treated *Notoedric* mange in cat with oral ivermectin, weekly twice @ 200 µg/ kg body weight [9]. But in the present study ivermectin was advised weekly thrice with slight higher dose rate than compare to the earlier studies. It was because of the more number of mites in the scrapings. Negre *et al.* evaluated the efficacy of different antifungal treatments for *Malassezia dermatitis* in dogs, in this use of only one topical treatment shampoo containing 2% miconazole and 2% chlorhexidine, twice a week for 3 weeks had also good therapeutic efficacy which can also used in the treatment of *Malassezia* in cats [10].

Conclusion

The present study reported the *Notoedres cati* was associated with *Malassezia* in a domestic cat with seborrhoea and pruritus. six doses of oral ivermectin @ 300 µg/ kg body weight, external application of shampoo which contains miconazole and chlorhexidine along with supportive therapy successfully cured the rare clinical condition in cat.

References

- [1]. Griffin C, Kwochka K, Macdonald (1993) Current Veterinary Dermatology. Mosby Publications. Linn, MO.
- [2]. Sugita T, Boekhout T, Guillot J (2010) Epidemiology. In: Velegraki A, Mayzner P, Gueho E, Boekhout T, editors. *Malassezia* and the skin. 1st ed. Berlin: Springer. 65-119.
- [3]. Khosravi AR, Shokri H, Rad MA, Jamshidi S (2009) Occurrence of *Malassezia* Species in Persian and Domestic Short Hair Cats with and without Otitis Externa. *J Vet Med Sci*, Dec 1
- [4]. Soulsby EJJ (1982) Helminths, arthropods and protozoa of domesticated animals, 7th Ed. Bailliere Tindall, London, 482-486.
- [5]. Senthil Kumar K, Selvaraj P, Vairamuthu S, Srinivasan SR, Kathiresan D (2008) Ivermectin Therapy In The Management Of *Notoedric* Mange In Cats. *Tamilnadu Journal of Veterinary & Animal Sciences* 4 (6) 240-241.
- [6]. Foil CS (2003) BSAVA Manual of Small Animal Dermatology. Edt. Foster, A.P. and Foil, C.S. 11th edn. BSAVA, Gloucester, UK.
- [7]. Cafarchia C, Otranto D (2008) The pathogenesis of *Malassezia* yeasts. *Parasitologia* 50(1-2): 65-67
- [8]. Ahman SE, Bergstrom KE (2009) Cutaneous carriage of *Malassezia* species in healthy and seborrheic Sphynx cats and a comparison to carriage in Devon Rex cats. *JFMS*, 11:970-976.
- [9]. Sivajothi S, Sudhakara Reddy B, Rayulu VC, Sreedevi C. *Notoedres cati* in cats and its management. *J Parasit Dis*. DOI 10.1007/s12639-013-0357-7.
- [10]. Negre A, Bensignor E, Guillot J (2009) Evidence-based veterinary dermatology: a systematic review of interventions for *Malassezia dermatitis* in dogs. *Veterinary Dermatology*, 20: 1-12.