

Association of Age and Gender to Custom Made Cast Post Given as Post Endodontic Restoration

Research Article

Thanish Ahamed S¹, Dr. Manish Ranjan^{2*}, Dr. Mebin George Mathew³

¹ Undergraduate Student, Saveetha Dental College and Hospital, Saveetha Institute of Medical and Technical Sciences, Saveetha University, Chennai 600077, Tamil Nadu, India.

² Associate Professor, Department of Conservative Dentistry and Endodontics, Saveetha Dental College and Hospital, Saveetha Institute of Medical and Technical Sciences, Saveetha University, Chennai 600077, Tamil Nadu, India.

³ Senior lecturer, Department of Pediatric Dentistry, Saveetha Dental College and Hospital, Saveetha Institute of Medical and Technical Sciences, Saveetha University, Chennai 600077, Tamil Nadu, India.

Abstract

Background: The successful treatment of teeth with substantial damage to the teeth structure not only depends on good endodontic treatment, but also on prompt post endodontic restoration of the tooth.

Aim and Objective: To assess the association of custom made cast post given as post endodontic restoration in various sex groups.

Materials and Methods: This retrospective study was conducted among outpatients reported to Saveetha Dental College and Hospitals, Chennai from June 2019 to March 2020. The study consisted of 80 subjects with custom made cast posts such as post endodontic restoration and was then correlated with various sex groups.

Results: Among the 80 study patients, 28 (35%) were females and 52 (65%) were males and the mean age group studied was 36.9 ± 13.6 years. The association between gender and the post endodontic restoration was not statistically significant ($p=0.639$).

Conclusion: In the present study, males were predominantly given custom made cast post as post endodontic restoration. Also, there was no significant association between gender and the post endodontic restoration.

Keywords: Custom Cast Post; Endodontic Restoration; Fibre Post; Post and Core Technique.

Introduction

Grossly decayed endodontically treated tooth with less coronal tooth structure remaining either due to a large pre-existing restoration or an extensive access at any preparation often pose a challenge while choosing an appropriate post-endodontic restorative material [1]. Clinicians always face the dilemma of whether to go for a direct/ indirect restoration, partial/full coverage crown, whether to go for post or not [2, 3].

An advanced stage of a tooth decay promotes an extremely damaged tooth that needs endodontic treatment to be restored [4]. When satisfactory coronal tooth structure remains, an artificial crown can be placed without a post [5, 6]. On the other hand, the treatment of severely damaged teeth often requires an endodontic

post.[7] The main reason for using post is to enable rebuilding of the tooth structure prior to crown restoration. [8-10] The fundamental requirements of posts include high tensile strength, high fatigue resistance to occlusal and shear loading and a good distribution of the forces affecting the tooth root [11, 12].

The primary purpose of a post is to retain a core in a tooth with extensive loss of coronal tooth structure [13 -15]. According to Franklin Weenie, most of the endodontically treated teeth often failed following root canal treatment owing to poor post endodontic restoration rather than primary endodontic cause [16]. Dentists believe that endodontic posts provide a stable and solid restoration of the tooth, as well as provides strengthening of the tooth root, which constitutes the solid basis for a dental crown restoration [17, 18]. However, some authors reported that the strength of the tooth is directly related to the remaining dentin,

***Corresponding Author:**

Dr. Manish Ranjan,

Associate Professor, Department of Conservative Dentistry and Endodontics, Saveetha Dental College and Hospital, Saveetha Institute of Medical and Technical Sciences, Saveetha University, Chennai 600077, Tamil Nadu, India.

Tel: +91- 9543445029

E-mail: manish@saveetha.com

Received: May 20, 2021**Accepted:** August 11, 2021**Published:** August 18, 2021

Citation: Thanish Ahamed S, Dr. Manish Ranjan, Dr. Mebin George Mathew. Association of Age and Gender to Custom Made Cast Post Given as Post Endodontic Restoration. *Int J Dentistry Oral Sci.* 2021;8(8):3945-3948. doi: <http://dx.doi.org/10.19070/2377-8075-21000807>

Copyright: Dr. Manish Ranjan©2021. This is an open-access article distributed under the terms of the Creative Commons Attribution License, which permits unrestricted use, distribution and reproduction in any medium, provided the original author and source are credited.

and because of that, an endodontic treatment can present a higher risk of biomechanical failure [19, 20].

A wide variety of post systems are available ranging from traditional cast metal posts to newer fiber posts [21]. The ease of use, less time consumption for fiber posts validates the utilization of fiber posts as an alternative to metal posts [22]. It doesn't mean custom made cast posts have lost their relevance in today's clinical practice.

Custom made cast posts are still a better option in cases where change in the angulation of the core is required and where there is more tooth structure loss [23]. Remaining coronal tooth structure following root canal therapy, functional requirements of the tooth, esthetics, age of patient and the existing periodontal condition have to be kept in mind while choosing an appropriate post endodontic restoration material [24].

Literature search reveals studies assessing the advantages of cast posts. However, there are no studies assessing the association of custom made cast post in various age and sex groups. To address this lacunae, this research was undertaken to assess the association of custom made cast post given as post endodontic restoration in various age and sex groups.

Previously our team has a rich experience in working on various research projects across multiple disciplines [25-39]. Now the growing trend in this area motivated us to pursue this project.

Materials and Methods

The present retrospective study was conducted among outpatients reported to the Department of Endodontics, Saveetha Dental College and Hospitals, Chennai from June 2019 to March 2020.

A total of 80 patients who had given custom made cast posts as post endodontic restoration were recruited as study participants. Data regarding gender and the teeth with custom made cast posts were collected and analysed. The study protocol was approved by Institutional Ethics and Review Board, Saveetha Dental College and Hospitals, Chennai.

The collected data was then entered in Microsoft Excel spreadsheet and analysed using SPSS software (IBM SPSS Statistics, Version 23). Descriptive statistics and inferential statistics was done for data summarization and presentation. Correlation analysis was done between age, gender and custom made cast post restoration as post endodontic restoration.

Results & Discussion

The study consisted of 80 patients with a mean age of 36.9 ± 13.6 years. Among 80 patients, 65% were males and 35% were females. (Figure 1) The association between gender and the teeth with custom made cast posts was studied. The association was found to be not statistically significant ($p = 0.693$). (Figure 3) At the same time, 47.5% of the patients belong to 15-34 years, 41.25% belong to 35-54 years and 11.25% belong to 55-74 years who underwent post endodontic restoration with custom made cast post. (Figure 2) The association between age and the number of post endodontic restoration was also not statistically significant ($p=0.124$). (Figure 4) In the present study, males were predominantly given custom made cast posts as post endodontic restoration compared to females and patients in the age group of 15 to 34 years old were having maximum number of cast post restorations but there was no statistically significant association between age or sex either.

The present study was conducted to assess the association of age and gender to custom made cast posts given as post endodontic

Figure 1: Bar chart showing distribution of gender with number of patients with custom made cast post. X-axis represents gender Female(blue) and male (green) and Y-axis represents the number of patients with custom made cast posts. 35% were females and 65% were males. Males were predominantly given custom made cast posts as post endodontic restoration compared to females.

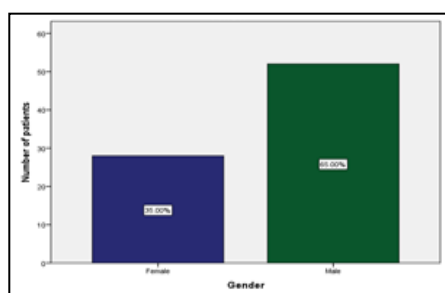


Figure 2: Bar chart showing distribution of patient's age with number of custom made cast posts. X-axis represents age groups [15-34 years(green), 35-54 years(purple) and 55-74 years(yellow)] and Y-axis represents the number of patients. 47.5% belong to 15-34 years, 41.25% belong to 35-54 years and 11.25% belong to 55-74 years. Patients belonging to 15-34 years were predominantly given custom made cast posts as post endodontic restoration followed by 35-54 years of age.

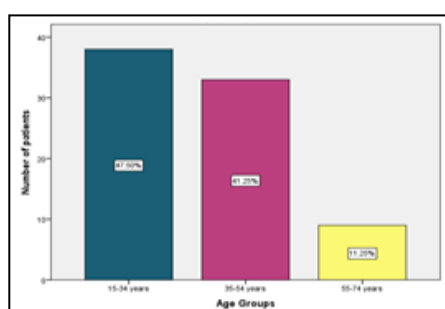


Figure 3: Bar graph depicts correlation between gender and number of teeth with custom made cast post. X-axis represents gender and Y-axis represents number of teeth with custom made cast posts. Pearson Chi square value - 12.520, df - 15, $p = 0.639 (>0.05)$ which was statistically not significant, However custom made cast posts were predominantly given in relation to upper central incisors in male particularly in tooth no 11.

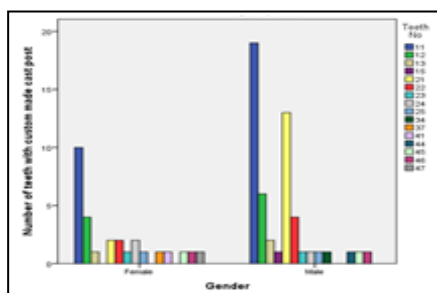
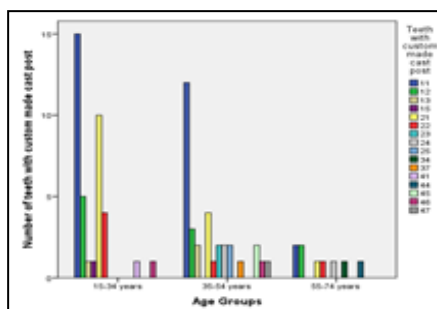


Figure 4: Bar graph depicts correlation between age groups and number of teeth with custom made cast post as post endodontic restorations. X-axis represents age groups and Y-axis represents the number of teeth with custom made cast posts. Pearson Chi square value - 39.088, df - 30, $p = 0.124 (>0.05)$ which is statistically not significant, However maximum number of custom made cast posts were done in the age group of 15 to 34 years.



restoration.

In the present study, among 80 patients with cast post as post endodontic restoration, 28 (35%) were females and 52 (65%) were males. Hence, males were predominantly given cast post as post endodontic restoration. This finding is in accordance with the previous study by Lynch D et al, in which the influence of coronal restoration type on the survival of endodontically treated teeth was assessed. In that study also the common gender in custom made cast post category was males [40].

To the best of our knowledge, this is the first study to assess the association of age, gender and custom made cast post given as post endodontic restoration. There are studies assessing the survival rate, influence of ferrule and risk factors of various endodontic restoration systems. However, this is the first study of its kind.

In the present study, the common age group was 15-34 years and the association between age and the cast post restoration is found to be statistically not significant ($p=0.124$). This is in contrary to the previous study by Hollanda AC et al, [41] where the common age group of patients with custom made cast posts was 46-60 years. This difference might be due to traumatic injuries which are prominent in the younger age group or because of ethnicity as the previous study was conducted among Brazilian population. Also in the present study the association between age and gender to the cast post restoration is found to be statistically not significant ($p=0.124$ and 0.693 respectively). This is in contrary to the previous study by Hollanda AC et al, [41] where significant association was observed. This might be because of the limited sample size of the present study.

To generalise the findings, however, more studies are required in

this field among the larger sample size. Also extensive research is needed to assess the other factors determining the choice of post given as post endodontic restoration.

Our institution is passionate about high quality evidence based research and has excelled in various fields [29], [42-51].

Conclusion

Within the limitations of the study, it can be concluded that males (65%) were predominantly given custom made cast posts as post endodontic restoration compared to females(35%) and patients with age groups of 15 to 34 years(47.50%) were involved mostly in post endodontic restoration with custom made cast post compared to other age groups.

References

- Choudhari S, Ranjan M. Knowledge, awareness, and perception regarding occlusal stamp technique for composite restorations. *Drug invent. today.* 2019 Oct 1;11(10).
- Kumar D, Antony S. Calcified canal and negotiation-A review. *Res J Pharm Technol.* 2018;11(8):3727-30.
- Ramamoorthi S, Nivedhitha MS, Divyanand MJ. Comparative evaluation of postoperative pain after using endodontic needle and EndoActivator during root canal irrigation: A randomised controlled trial. *Aust Endod J.* 2015 Aug;41(2):78-87. Pubmed PMID: 25195661.
- Noor SS. Chlorhexidine: Its properties and effects. *Res J Pharm Technol.* 2016;9(10):1755-60.
- Gopalsamy K, Ranjan M. Knowledge, awareness and perception of cention being used as a replacement for amalgam restoration. *Int. J. Pharm. Sci. Res.* 2020;11:7-12.
- Prabha JL, Ranjan M. Effect of total etch on enamel. *Res J Pharm Technol.* 2018;11(6):813-2633.
- Ramanathan S, Solete P. Cone-beam Computed Tomography Evaluation of Root Canal Preparation using Various Rotary Instruments: An in vitro Study. *J Contemp Dent Pract.* 2015 Nov 1;16(11):869-72.
- Teja KV, Ramesh S, Priya V. Regulation of matrix metalloproteinase-3 gene

- expression in inflammation: A molecular study. *J Conserv Dent.* 2018 Nov;21(6):592-596.
- [9]. Rajendran R, Kunjusankaran RN, Sandhya R, Anilkumar A, Santhosh R, Patil SR. Comparative evaluation of remineralizing potential of a paste containing bioactive glass and a topical cream containing casein phosphopeptide-amorphous calcium phosphate: An in vitro study. *Pesqui. Bras. Odontopediatria Clin. Integr.* 2019 Oct 10;19.
- [10]. Hussainy SN, Nasim I, Thomas T, Ranjan M. Clinical performance of resin-modified glass ionomer cement, flowable composite, and polyacid-modified resin composite in noncarious cervical lesions: One-year follow-up. *J Conserv Dent.* 2018 Sep-Oct;21(5):510-515. Pubmed PMID: 30294112.
- [11]. Siddique R, Sureshbabu NM, Somasundaram J, Jacob B, Selvam D. Qualitative and quantitative analysis of precipitate formation following interaction of chlorhexidine with sodium hypochlorite, neem, and tulsi. *J Conserv Dent.* 2019 Jan-Feb;22(1):40-47. Pubmed PMID: 30820081.
- [12]. Rajakeerthi R, Nivedhitha MS. Natural Product as the Storage medium for an avulsed tooth—A Systematic Review. *Cumhur. Dent. J.* 2019 Jun 11;22(2):249-56.
- [13]. Teja KV, Ramesh S. Shape optimal and clean more. *Saudi Endod. J.* 2019 Sep 1;9(3):235.
- [14]. Jose J, Subbaiyan H. Different treatment modalities followed by dental practitioners for Ellis class 2 fracture—A questionnaire-based survey. *Open Dent J.* 2020 Feb 18;14(1):59-65.
- [15]. Janani K, Palanivelu A, Sandhya R. Diagnostic accuracy of dental pulse oximeter with customized sensor holder, thermal test and electric pulp test for the evaluation of pulp vitality: an in vivo study. *Braz. Dent. Sci.* 2020 Jan 31;23(1):8.
- [16]. Weine FS. *Endodontic therapy*, st. Louis: CV Mosby.1982.
- [17]. Nandakumar M, Nasim I. Comparative evaluation of grape seed and cranberry extracts in preventing enamel erosion: An optical emission spectrometric analysis. *J Conserv Dent.* 2018 Sep-Oct;21(5):516-520. Pubmed PMID: 30294113.
- [18]. Manohar MP, Sharma S. A survey of the knowledge, attitude, and awareness about the principal choice of intracanal medicaments among the general dental practitioners and nonendodontic specialists. *Indian J Dent Res.* 2018 Nov-Dec;29(6):716-720. Pubmed PMID: 30588997.
- [19]. Ravinthar K. Recent advancements in laminates and veneers in dentistry. *Res J Pharm Technol.* 2018;11(2):785-7.
- [20]. S TA, Department of Conservative Endodontics, Dental S, College, Jayalashmi, Department of Conservative Endodontics, Dental S, College. Endodontic management hot tooth in clinical practice -a questionnaire survey. *Int. J. Curr. Adv. Res.* 2017; 6:2819-2821
- [21]. Balkenhol M, Wöstmann B, Rein C, Ferger P. Survival time of cast post and cores: a 10-year retrospective study. *J Dent.* 2007 Jan;35(1):50-8. Pubmed PMID: 16750593.
- [22]. Cheung W. A review of the management of endodontically treated teeth: Post, core and the final restoration. *J Am Dent Assoc.* 2005 May 1;136(5):611-9.
- [23]. Ray HA, Trope M. Periapical status of endodontically treated teeth in relation to the technical quality of the root filling and the coronal restoration. *Int Endod J.* 1995 Jan;28(1):12-8.
- [24]. Gómez-Polo M, Llidó B, Rivero A, Del Río J, Celemín A. A 10-year retrospective study of the survival rate of teeth restored with metal prefabricated posts versus cast metal posts and cores. *J Dent.* 2010 Nov;38(11):916-20. Pubmed PMID: 20713117.
- [25]. Govindaraju L, Gurunathan D. Effectiveness of Chewable Tooth Brush in Children—A Prospective Clinical Study. *J Clin Diagn Res.* 2017 Mar;11(3):ZC31-ZC34. Pubmed PMID: 28511505.
- [26]. Christabel A, Anantanarayanan P, Subash P, Soh CL, Ramanathan M, Muthusekhar MR, et al. Comparison of pterygomaxillary dysjunction with tuberosity separation in isolated Le Fort I osteotomies: a prospective, multi-centre, triple-blind, randomized controlled trial. *Int J Oral Maxillofac Surg.* 2016 Feb;45(2):180-5. Pubmed PMID: 26338075.
- [27]. Soh CL, Narayanan V. Quality of life assessment in patients with dentofacial deformity undergoing orthognathic surgery—a systematic review. *Int J Oral Maxillofac Surg.* 2013 Aug;42(8):974-80. Pubmed PMID: 23702370.
- [28]. Mehta M, Deeksha, Tewari D, Gupta G, Awasthi R, Singh H, et al. Oligonucleotide therapy: An emerging focus area for drug delivery in chronic inflammatory respiratory diseases. *Chem Biol Interact.* 2019 Aug 1;308:206-215. Pubmed PMID: 31136735.
- [29]. Ezhilarasan D, Apoorva VS, Ashok Vardhan N. Syzygium cumini extract induced reactive oxygen species-mediated apoptosis in human oral squamous carcinoma cells. *J Oral Pathol Med.* 2019 Feb;48(2):115-121. Pubmed PMID: 30451321.
- [30]. Campeau PM, Kasperaviciute D, Lu JT, Burrage LC, Kim C, Hori M, et al. The genetic basis of DOORS syndrome: an exome-sequencing study. *Lancet Neurol.* 2014 Jan;13(1):44-58. Pubmed PMID: 24291220.
- [31]. Sneha S. Knowledge and awareness regarding antibiotic prophylaxis for infective endocarditis among undergraduate dental students. *Asian J Pharm Clin Res.* 2016 Oct 1;154-9.
- [32]. Christabel SL, Linda Christabel S. Prevalence of type of frenal attachment and morphology of frenum in children, Chennai, Tamil Nadu. *World J Dent.* 2015 Oct;6(4):203-7.
- [33]. Kumar S, Rahman R. Knowledge, awareness, and practices regarding biomedical waste management among undergraduate dental students. *Asian J Pharm Clin Res.* 2017;10(8):341.
- [34]. Sridharan G, Ramani P, Patankar S. Serum metabolomics in oral leukoplakia and oral squamous cell carcinoma. *J Cancer Res Ther.* 2017 Jul 1;13(3):556-561.
- [35]. Ramesh A, Varghese SS, Doraiswamy JN, Malaiappan S. Herbs as an antioxidant arsenal for periodontal diseases. *J Intercolt Ethnopharmacol.* 2016 Jan 27;5(1):92-6. Pubmed PMID: 27069730.
- [36]. Thamaraiselvan M, Elavarasu S, Thangakumaran S, Gadagi JS, Arthie T. Comparative clinical evaluation of coronally advanced flap with or without platelet rich fibrin membrane in the treatment of isolated gingival recession. *J Indian Soc Periodontol.* 2015 Jan;19(1):66-71.
- [37]. Thangaraj SV, Shyamsundar V, Krishnamurthy A, Ramani P, Ganesan K, Muthuswami M, et al. Molecular Portrait of Oral Tongue Squamous Cell Carcinoma Shown by Integrative Meta-Analysis of Expression Profiles with Validations. *PLoS One.* 2016 Jun 9;11(6):e0156582. Pubmed PMID: 27280700.
- [38]. Ponnulakshmi R, Shyamaladevi B, Vijayalakshmi P, Selvaraj J. In silico and in vivo analysis to identify the antidiabetic activity of beta sitosterol in adipose tissue of high fat diet and sucrose induced type-2 diabetic experimental rats. *Toxicol Mech Methods.* 2019 May;29(4):276-290. Pubmed PMID: 30461321.
- [39]. Ramakrishnan M, Shukri M. Fluoride, Fluoridated Toothpaste Efficacy And Its Safety In Children—Review. *Int J Pharm Res.* 2018 Oct 1;10(04):109-14.
- [40]. Lynch CD, Burke FM, Ríordáin N, Hannigan A. The influence of coronal restoration type on the survival of endodontically treated teeth. *Int. J. Curr. Adv. Res.* 2004 Dec 1;12(4):171-6.
- [41]. Hollanda AC, de Alencar AH, Estrela CR, Bueno MR, Estrela C. Prevalence of endodontically treated teeth in a Brazilian adult population. *Braz Dent J.* 2008;19(4):313-7. Pubmed PMID: 19180320.
- [42]. Vijayashree Priyadharsini J. In silico validation of the non-antibiotic drugs acetaminophen and ibuprofen as antibacterial agents against red complex pathogens. *J Periodontol.* 2019 Dec;90(12):1441-1448. Pubmed PMID: 31257588.
- [43]. Pc J, Marimuthu T, Devadoss P, Kumar SM. Prevalence and measurement of anterior loop of the mandibular canal using CBCT: A cross sectional study. *Clin. Implant Dent. Relat. Res.* 2018 Apr 6;20(4):531-4.
- [44]. Ramesh A, Varghese S, Jayakumar ND, Malaiappan S. Comparative estimation of sulfiredoxin levels between chronic periodontitis and healthy patients - A case-control study. *J Periodontol.* 2018 Oct;89(10):1241-1248. Pubmed PMID: 30044495.
- [45]. Ramadurai N, Gurunathan D, Samuel AV, Subramanian E, Rodrigues SJ. Effectiveness of 2% Articaine as an anesthetic agent in children: randomized controlled trial. *Clin Oral Investig.* 2019 Sep;23(9):3543-50.
- [46]. Sridharan G, Ramani P, Patankar S, Vijayaraghavan R. Evaluation of salivary metabolomics in oral leukoplakia and oral squamous cell carcinoma. *J Oral Pathol Med.* 2019 Apr;48(4):299-306.
- [47]. Mathew MG, Samuel SR, Soni AJ, Roopa KB. Evaluation of adhesion of *Streptococcus mutans*, plaque accumulation on zirconia and stainless steel crowns, and surrounding gingival inflammation in primary molars: randomized controlled trial. *Clin Oral Investig.* 2020 Sep;24(9):1-6. Pubmed PMID: 31955271.
- [48]. Samuel SR. Can 5-year-olds sensibly self-report the impact of developmental enamel defects on their quality of life? *Int J Paediatr Dent.* 2021 Mar;31(2):285-286. Pubmed PMID: 32416620.
- [49]. R H, Ramani P, Ramanathan A, R JM, S G, Ramasubramanian A, et al. CYP2 C9 polymorphism among patients with oral squamous cell carcinoma and its role in altering the metabolism of benzo[a]pyrene. *Oral Surg Oral Med Oral Pathol Oral Radiol.* 2020 Sep;130(3):306-312. Pubmed PMID: 32773350.
- [50]. Chandrasekar R, Chandrasekar S, Sundari KKS, Ravi P. Development and validation of a formula for objective assessment of cervical vertebral bone age. *Prog Orthod.* 2020 Oct 12;21(1):38. Pubmed PMID: 33043408.
- [51]. Vijayashree Priyadharsini J, Smiline Girija AS, Paramasivam A. In silico analysis of virulence genes in an emerging dental pathogen *A. baumannii* and related species. *Arch Oral Biol.* 2018 Oct;94:93-98. Pubmed PMID: 30015217.