

## Medical Emergencies In Dentistry – A Guide To A Successful Practise

Research Article

Saraswathi Gopal. K<sup>1\*</sup>, Sangavi. R<sup>2</sup>, Mahesh Kumar .P<sup>3</sup>

<sup>1</sup> Faculty of Dentistry, Department of Oral Medicine and Radiology, Meenakshi Academy of Higher Education & Research; Meenakshi Ammal Dental College, Chennai, Tamil Nadu, India.

<sup>2</sup> Postgraduate student, Department of Oral Medicine and Radiology, Meenakshi Academy of Higher Education & Research; Meenakshi Ammal Dental College, Chennai, Tamil Nadu, India.

<sup>3</sup> Faculty of Dentistry, Department of Oral Medicine and Radiology, Meenakshi Academy of Higher Education & Research; Meenakshi Ammal Dental College, Chennai, Tamil Nadu, India.

### Introduction

An emergency is a medical condition that requires immediate attention and successful management. It is an unforeseen event that leads to bodily injury, central nervous system stimulation and depression, respiratory, circulatory disturbances, and allergic reactions, etc [1]. An emergency is a medical condition that demands immediate attention and successful management. It is an unforeseen event that leads to bodily injury, central nervous system stimulation and depression, respiratory, circulatory disturbances, and allergic reactions, etc [1]. These are the life-threatening situations of which every dental practitioner must be aware so that unwanted morbidity can be avoided. Dentists, through their knowledge, should be familiar with the prevention, diagnosis, and management of common emergencies. In addition, the dentist should be well trained and be aware of what to be done and can act promptly. As these skills are not used every day, regular review is necessary at least annually but preferably more often.[2] Emergencies can be prevented to a certain extent by recording a detailed medical history, doing a complete physical examination, and thorough patient monitoring throughout the procedure. Preparation for an emergency and sound knowledge about the management of all emergencies, in general, is of major concern to dental specialists these are the life-threatening situations of which every practitioner must be aware so that unwanted morbidity can be avoided. Dentists, through their knowledge, should be familiar with the prevention, diagnosis, and management of common emergencies. In addition, the dentist should be well trained and be aware of what to be done and can act promptly. As these skills are not used every day, regular review is necessary at least annually but preferably more often.[2] Emergencies can be prevented to a certain extent by recording a detailed medical history, doing a complete physical examination, and thorough patient monitor-

ing throughout the procedure. Preparation for an emergency and sound knowledge about the management of all emergencies, in general, is of major concern to dental specialists.

### Basic Principles Of Management Of Medical Emergencies

The basic algorithm in managing any emergency is rendering basic life support (BLS) measures and cardiopulmonary resuscitation (CPR). This is done by following the basic principles: Position (P), Airway (A), Breathing (B), Circulation (C), and Definitive therapy (D) [1]. The basic positions to manage an emergency are supine position, Trendelenburg position, and semi-erect position. Maintaining a patent and functioning airway is the first and important procedure in managing an emergency. This is achieved usually by the head tilt-chin lift maneuver. [4] If the patent airway is not achieved, then invasive procedures like direct laryngoscopy and cricothyrotomy can be carried out. The next priority is to check for the presence of adequate breathing is assessed by the look-feel and listen-to technique.[2] If spontaneous breathing is not evident then rescue breathing should be initiated immediately either by the mouth-to-mouth technique or the bag-valve-mask technique. Once patent airway patent and breathing is established, circulation is assessed. The ideal and reliable method is by palpating the carotid pulse at the region of the sternocleidomastoid muscle. In case of absence of pulse, then CPR is initiated immediately. When airway, breathing, and circulation are maintained, definitive treatment is initiated. Definitive therapy involves the administration of an ideal drug to relieve symptoms. The medical emergencies that are commonly encountered in dental practice such as syncope, airway obstruction, anaphylaxis, local anesthetic toxicity, asthmatic attack, chest pain, hemorrhage, and seizure. Analysis of the history, patient counseling, and motivation plays a

#### \*Corresponding Author:

Saraswathi Gopal. K,  
Faculty of Dentistry, Department of Oral Medicine and Radiology, Meenakshi Academy of Higher Education & Research; Meenakshi Ammal Dental College, Chennai, Tamil Nadu, India.  
Tel: 09940588033  
E-mail: sangaviramesh12@gmail.com

Received: July 17, 2021

Accepted: November 10, 2021

Published: November 12, 2021

**Citation:** Saraswathi Gopal. K, Sangavi. R, Mahesh Kumar .P. Medical Emergencies In Dentistry – A Guide To A Successful Practise. *Int J Dentistry Oral Sci.* 2021;8(11):4991-4996. doi: <http://dx.doi.org/10.19070/2377-8075-210001005>

**Copyright:** Saraswathi Gopal. K©2021. This is an open-access article distributed under the terms of the Creative Commons Attribution License, which permits unrestricted use, distribution and reproduction in any medium, provided the original author and source are credited.

key role in reducing emergencies.

## Syncope

Syncope is a general term referring to a sudden, transient loss of consciousness that usually occurs secondary to a period of cerebral ischemia.[3] The predisposing factors for syncope are of two types 1) psychogenic factors and 2) nonpsychogenic. The psychogenic factors for syncope are Fright, Anxiety, Emotional stress, undesirable news, Sight of blood/surgical/dental instruments Non -Psychogenic factors are Erect sitting or standing, posture, starvation or a missed meal, Exhaustion, Poor physical condition humid, crowded environment. Before going into syncope patient will have certain signs and symptoms such as Warm feeling in face and neck, pale or ashen coloration, sweating, feels cold, abdominal discomfort, lightheadedness or dizziness, mydriasis (Pupillary dilatation.), Yawning, Increased heart rate, a slight decrease in blood pressure this is termed as known as presyncope period. During syncope, the patient loses consciousness. Generalized muscle relaxation will happen, Bradycardia (Weak thready pulse, Seizure (Twitching of hands, legs, and face.), Eyes open (Out and up gaze.) Once the patient recovers during the post syncope period there will be a Variable period of mental confusion, Heart rate increases (Strong rate and rhythm.), Blood pressure back to normal levels.

### Pathophysiology of syncope

The critical level of cerebral blood flow to maintain consciousness is 30ml per 100gm per min when this level is not achieved patient experiences syncope. When the body experiences Stress the Catecholamines get released into the blood, this is the body's response to stress it is known as the " fight or flight " response. Increased catecholamines will lead to changes in tissue blood perfusion and decrease peripheral vascular resistance and increase the blood flow to many tissues especially the skeletal muscles for the muscular action to take place. If the expected muscular action takes place the muscle will pump the blood back to the heart so the blood pressure remains at a base level so the signs of syncope don't occur. when the muscular activity doesn't take place, the patient remains static in the dental chair. The blood starts pooling in the periphery which leads to decreased cardiac output followed by decreased in circulating blood volume and decreased arterial BP this ultimately leads to decreased cerebral blood flow.[3]

### Management of syncope

Check ABC Assess & open airway (head tilt & chin lift); assess airway patency & breathing; assess circulation (palpation of carotid pulse). Move on to definitive management administer O2. Monitor vital signs. Administer aromatic ammonia vapor which is a respiratory stimulant that helps to increase breathing and muscular movement. Administer atropine 0.5mg either in IV or IM if bradycardia persists. Once the patient recovers dental treatment should be postponed [4].

### Postural Hypotension

Postural hypotension also known as orthostatic hypotension is defined as a drop in systolic blood pressure (BP) of at least 20 mm Hg or of diastolic BP of at least 10 mm Hg within 3 minutes of standing erect when compared with blood pressure from the sitting or supine position. The predisposing factors of postural hypotension are Drugs such as anti-hypertensive, opioids and histamine blockers, Prolonged period of recumbency or convalescence, Inadequate postural reflex, Late-stage pregnancy, Advanced age, Venous defects in legs Physical exhaustion and starvation, Chronic postural hypotension (Shy – Drager syndrome). The patient will experience feeling lightheaded or dizziness, Blurry vision, Weakness, Confusion, Nausea. All these ultimately lead to fainting after standing up [3].

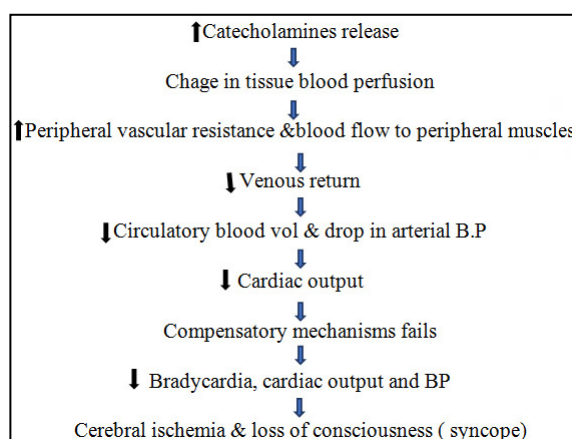
### Pathophysiology of postural hypotension

When the patient is in the supine position the blood pressure is equally distributed throughout the body When the body alters the position to Semi supine the BP decreases by 2mm Hg for every 1 inch when the patient moves into supine to upright the Influence of gravity in CVS is increased. Baroreceptor will sense this variation in BP and increase the heart rate and venous constriction this aids in the return of blood to the right side of the heart.

### Management

The patient must be placed in a supine position with feet elevated. ABC Assessed following which oxygen is administered at the rate of 8-15ml per minute. patients vital signs are monitored and chair reposition should be done slowly.

Chart 1. Mechanism of syncope.



## Foreign Body Airway Obstruction

Airway obstruction is generally caused due to accidental slippage, aspiration of foreign objects, or laryngeal spasm. During dental treatment, there is great potential for tiny objects to drop into the posterior portion of the oral cavity and subsequently into the pharynx.[3] Usage of Rubber dam, Gauze, Suction, Magill's intubation forceps, Ligature using dental floss Can help in preventing the intraoral objects from slipping inside the airway.[5]

### Signs and symptoms

The patient will Gasp for breath, grabs at the throat, Panic, Suprasternal or supraclavicular retraction, Inability to speak, breathe, cough these are general signs and symptoms. When there is partial obstruction patient might experience Snoring, Wheezing, Crowing sound on inspiration, Forceful cough, wheezing between cough, Absent or altered voice sounds, disorientation, when there is complete obstruction patient will not be able to make any noise. [3, 4]

### Management

If the object is visible with the help of the assistant place the patient in a supine position or Trendelenburg position, the object is retrieved using Magill intubation forceps, in the absence of an assistant instruct the patient to bend over the arm of the chair with their head down and Encourage the patient to cough to expectorate the object. If it fails Kneel or stands behind the victim and wraps arms around the victim's waist and makes a fist with one hand, Place the thumb side of the fist against the victim's abdomen [3, 6]. The hand should rest in the midline, slightly above the umbilicus, and well below the tip of the xiphoid process Fist is held with the other hand and pressed into the patient's abdomen with a rapid, forceful upward thrust. This can be repeated until the object is expected. In the case of infants Back slaps can be performed the infant is straddled over the rescuer's arm with the head lower than the trunk. Using the heel of the hand, the rescuer delivers up to five back slaps forcefully between the infant's shoulder blades to dislodge the foreign body. If the foreign body is not recovered Radiologist should be consulted and Obtain appropriate radiographs and initiate medical consultation and Perform bronchoscopy to visualize and retrieve the foreign body [3].

## Asthma

Asthma is a chronic inflammatory disorder of the airways it is characterized by recurrent and often irreversible airflow limitations due to underlying inflammatory processes. Due to the inflammatory reaction airway is filled with inflammatory cells will lead to the deposition of collagen, mast cells will degranulate, and leads to increased capillary permeability and edema formation which leads to bronchospasm.[7] Patients might experience Intermittent wheezing, Feeling of chest tightness, Dyspnea, Cough, Agitations, Tachypnea. Precautions to be taken before treating asthma patients. Confirm that they have taken their most recent scheduled dose of medication, The patient's metered-dose inhaler bronchodilator should be on hand, Procedure should be done late morning/afternoon, Emergency kit with a bronchodilator and oxygen should be available, Avoid L. A with sodium metabisul-

phite, avoid using dental materials that may elicit an asthmatic attack i.e., dentifrices, fissure sealants, methyl methacrylate, fluoride trays & cotton rolls which can trigger asthmatic events should be avoided [8].

### Management

The patient is positioned upright with arms thrown forward. A, B, C is assessed. O<sub>2</sub> and bronchodilators are administered via inhalation. If the episode continues, epinephrine is administered subcutaneously 0.01mg/kg up to 0.3 mg. When the episode subsides discharge the patient and postpone the dental treatment if it continues activate EMS.[9]

## Diabetes Mellitus

Diabetes is the most common endocrine disorder. It is marked by high levels of blood glucose resulting from defects in insulin production, insulin action, or both.

### Cardinal Features

polydipsia, polyuria, polyphagia, weight loss, poor wound healing, weakness, frequent infections, obesity are the general symptoms of diabetes.[7] xerostomia, burning sensations, gingival hyperplasia, dental caries, periodontal disease, and candidal infections, fruity (acetone) breath, the thickness of saliva are Oral manifestations of diabetes.

### Management

Patient with known diabetes Enquires about the Type, Medication, dosage, date of the last visit, and HbA1c values. When a patient is under control without serious complications dental procedures can be carried out with precautions, Morning appointments are preferred, during the procedure should be short, source of glucose must be available in the dental office.[10] Insulin shock occurs when blood glucose drops below 60 mg/dL in this condition. confusion, sweating, tremors, agitation, anxiety, dizziness, tingling or numbness, and tachycardia. Severe hypoglycemia may result in seizures or loss of consciousness are the signs a patient will develop in a dental chair during insulin shock. If the patient is conscious administer 15g of oral carbohydrate. In unconscious patients, 50ml of dextrose is given in 50% concentration or 1mg glucagon intravenously, or give 1ml glucagon intramuscularly at almost any body site. Following the treatment, the signs and symptoms of hypoglycemia should resolve in 10 to 15 minutes, once stabilized, the patient is transported to a hospital for definitive care and observation. Postpone the dental procedure. When the condition doesn't cease activate EMS [3].

## Seizures

Seizures are a paroxysmal event due to abnormal, excessive, hypersynchronous discharge from neuronal aggregates in the CNS. Seizures are not considered to be life-threatening except when followed by one another closely for an extended period. Emergency management of a patient experiencing a seizure is essentially preventing injury during the seizure and supportive therapy post-seizure There are three main types of seizures Focal-partial seizure, Generalized. A generalized seizure is further

divided into three types Grand mal (tonic-clonic seizure), Petit Mal (absence seizure), Status epilepticus [11].

### Clinical features

During the prodromal phase, the patient may exhibit changes that may be evident only to a relative, such as increased anxiety or depression. A patient with a history of seizures may recognize the development of an "aura" consisting of olfactory, visual, gustatory, or auditory changes, during aura, treatment should be terminated immediately before it progresses to the preictal phase. In the preictal phase, patients will experience, myoclonic jerks, Diaphragmatic muscles go into spasm. The ictal phase has Alternating muscular relaxation and violent contractions along with frothing and bleeding at the mouth Bleeding lasts for 2 to 5 minutes. In the postictal phase, Tonic-colonic movements cease. Breathing returns to normal. Consciousness gradually returns with disorientation, relaxation occurs. These patients will have total amnesia of the seizure [7].

### Management

Recognize the problem (lack of response to stimulation). Place the patient's supine position in the dental chair. Once the seizure ceases (<5 minutes) reassure the patient. If intravenous access is available diazepam (Valium) IV is administered at a dose of 0.2-0.5mg for Child lesser than 5 years 0.2-0.5 mg slowly every 2-5 minutes with a maximum of 5mg, above 5 years [3, 7].

When the episode terminates allow the patient to recover, discharge the patient with attender, postpone dental procedures. If the condition pertains to more than 5mins activate EMS and start with BLS until the medical help reaches.

### Allergic reactions

Allergy has been defined as a hypersensitive state acquired through exposure to a particular allergen, reexposure to which produces a heightened capacity to react., involving the release of mediators from mast cells. which occur within minutes, or up to a few hours, after exposure to a provoking agent.[13] It can be mild, moderate, or severe. The majority of cases are mild but any anaphylaxis has the potential to become life-threatening" Anaphylaxis develops rapidly, reaches peak severity within 5-30 min. It is usually life-threatening due to respiratory embarrassment.

### Symptoms and signs include

The sensation of warmth, itching especially in the axilla and groin, feeling of anxiety. Angioedema of the lip and tongue is seen at early stages. Later these may progress into an erythematous rash(urticaria), edema of the face and neck, bronchospasm, and laryngeal edema.[3]

Pathophysiology of an anaphylactic reaction.

When an antigen and allergen invade the body for the first time, the B cells will produce IgE antibodies against that particular antigen. The IgE antibody binds to the surface of mast cells and basophils when there is a subsequent exposure to the same antigen, the antigen will bridge the gap between to IgE molecule which will lead to degranulation of the cell and release of histamine and

other inflammatory mediators. The sudden release results in a drop in blood pressure, flushing, itching, potentially respiratory compromise, and potential death.[15]

### Management

The first step is to Identify an anaphylactic reaction and to remove the potential. The patient is shifted to supine position. If breathing is difficult, allow them to sit Airway, breathing, circulation is should be assessed. A Dose of 0.3-0.5mg epinephrine (1:1000) is administered intramuscularly and repeat every 5 minutes as needed [14].

### Angina

Angina is defined as a characteristic thoracic chest pain usually substernal precipitated by exercise, emotion, and relieved by vasodilator drugs.[20] The major clinical characteristic of angina is chest pain. The sensation is defined as dull, aching, discomfort, constricting, suffocating, crushing, heavy, and squeezing.

### Dental therapy consideration

Prevention of acute episodes of angina during dental treatment is achieved by minimizing stress so that the myocardial oxygen demand of the patient is met. The stress reduction protocol is particularly important in the management of the anginal patient. Specific consideration must be given to the length of the appointment, pain control during the treatment, and the use of sedation. [18]. Patients with unstable or daily anginal episodes should be considered for dental care limited to emergency treatment only after consultation with the patient's physician. Local Anaesthesia without a vasoconstrictor is advised for these patients to avoid angina episodes.

### Management

Recognize the problem and terminate the dental treatment. Position the patient comfortably on the dental chair perfectly supine position. Assess A, B, C. Administer oxygen via nasal cannula and nitroglycerine sublingually around 0.3-0.6mg [6]. Nitroglycerine eliminates the pain in 2-4 mins, when pain resolves allow the patient to rest and postpone the dental treatment. If the pain doesn't resolve administer aspirin around 160-325mg, monitor the vital signs, and active EMS

### Management Of Pregnant Patients

Treatment of pregnant patients has the potential to affect the lives of two separate individuals. Certain principles must be considered in the treatment of pregnant patients so that, it benefits the mother while minimizing the risk to the fetus.

Dental treatments can be modified but need not be withheld, provided that the risk assessment is made properly.

The most commonly encountered problem in treating pregnant women is a supine hypotensive syndrome, when a pregnant woman is placed on a dental chair for a prolonged period it will compress the inferior vena cava this leads to a decrease in arterial oxygen tension and decreased uteroplacental perfusion with Increased risk of developing deep vein thrombosis.[18] To avoid



this patient should be tilted laterally around 5-15% on her left side.

During the first Trimester rapid cell division and active organogenesis occur between the second and the eighth week of post-conception. Therefore, there is a high risk of susceptibility to stress and teratogens. 50% to 75% of all spontaneous abortions occur during this period. So, the dental treatments are limited to periodontal prophylaxis and emergency treatments only.[20]

During the second trimester the risk to the fetus is low as organogenesis gets completed. Few elective and emergency dentoalveolar procedures are more safely accomplished during the second trimester.[20]

During the third trimester, the pregnant mother may experience discomfort on the dental chair. Short dental appointments should be scheduled with appropriate positioning in the chair. It is safe to perform routine dental treatment in the early part of the third trimester.[20]

A radiation dose of 10 Gy causes congenital fetal abnormalities. The exposure of any radiographic films required for the management of the pregnant patient in most situations should not place the fetus at increased risk. Adequate shielding and protective equipment must be used at all times.[19]

### Haemorrhage

A hemorrhage is referred to as Prolonged or uncontrolled bleeding. Hemorrhage is most commonly encountered in a dental setup during extractions and minor surgical procedures. The medical history of the patient plays an important role in the Management of these patients. Make sure whether the patient is hematologically normal or suffers from some disturbance in the normal clotting mechanism. Uncontrolled and prolonged bleeding can occur in some healthy patients after dental extraction.[7]

Local causes of hemorrhage originate in either soft tissue or bone it is either arterial, venous, or capillary. Systemic causes include patients with hereditary conditions such as hemophilia, Von Willebrand's disease, thrombocytopenia are susceptible to hemor-

rhage following oral surgical procedures.

### Local Management

Ligation of blood vessels, use of pressure packs, electrocautery, hemostatic agents like vasoconstrictors in L.A. are used for local management.

### Systemic Management

Patients with mild bleeding disorders can be treated in a primary care setting after consultation with the hematologist. Patients with a moderate to severe level of bleeding disorder require invasive dental procedures are best treated in a hospital setting. Before any extractions or minor oral surgical procedures, a Complete blood count should be performed. There is an 80% chance that a hemophilic patient to develop a hematoma following the administration of an inferior alveolar nerve block. The hematoma could be fatal if it accumulates in the mediastinum and compromises the airway. Preoperative prophylactic coverage should be discussed with the hematologist.[23] Mental nerve block injection is considered safe and requires no hematologic coverage before administration. A mild form of hemophilia A and vWD are normally treated pre-operatively by desmopressin acetate. It can be administered intravenously, subcutaneously, intranasally.[22] In severe forms before dental extractions, patients require replacement therapy with factor VIII as a prophylactic option and/or as emergency treatment in case of prolonged bleeding. It is recommended to deliver the intended dental treatment within 30-60 minutes following its administration. It is necessary to measure the level of factor VIII in patients with hemophilia A before any invasive dental procedures. Tranexamic acid is given in the form of mouthwash with a concentration of 15-25 mg/kg 4 times a day for 7-10 days; or oral administration of tablets of 1 g, 3 times a day for 7-10 days. This helps to add stability to the clot.

### Conclusion

When we are prepared for an emergency, the emergency ceases to exist. Measures should be taken to make sure the dental team is well prepared to meet any medical crisis. Thorough knowledge is required to understand the patient's medical conditions to deter-

Chart 2. Safe drugs during pregnancy.

DRUGS	INDICATED	CONTRAINDICATION
ANALGESICS	Acetaminophen	Aspirin
	morphine	ibuprofen
ANTIBIOTICS	Amoxicillin	Tetracycline
	cephalosporin	Erythromycin
LOCAL ANESTHETICS	Lidocaine	Mepivacaine
	Prilocaine	Bupivacaine
		Benzodiazepens
ANTIFUNGALS	Clotrimazole	Fluconazole
	nystatin	Ketoconazole
ANTACIDS	Omeprazole	misoprostol
	pantoprazole	
ANTIHISTAMINE	Cetirizine	Fexofenadine

mine the risk factors associated with the condition. Modifications of the treatment protocol are essential to handle patients with a known history of certain medical conditions this helps to minimize the risk. The dental team should exercise extreme caution to identify the early signs and symptoms of an impending medical emergency and render early and rapid treatment. Prompt recognition and efficient management of medical emergencies by a well-prepared dental team help to save lives.

## References

- [1]. Prasad KD, Hegde C, Alva H, Shetty M. Medical and dental emergencies and complications in dental practice and its management. *Journal of Education and Ethics in Dentistry*. 2012 Jan 1;2(1):13.
- [2]. Council R. Medical emergencies and resuscitation: standards for clinical practice and training for dental practitioners and dental care professionals in general dental practice. Resuscitation Council (UK); 2008.
- [3]. Malamed SF. *Medical Emergencies in the Dental Office-E-Book*. Elsevier Health Sciences; 2014 Oct 27.
- [4]. Oujwoswini A. Management of Medical Emergencies in Dental Office. *Indian Journal of Public Health Research & Development*. 2019;10(9):1701-4.
- [5]. Tiwana KK, Morton T, Tiwana PS. Aspiration and ingestion in dental practice: a 10-year institutional review. *J Am Dent Assoc*. 2004 Sep;135(9):1287-91. PubMed PMID: 15493393.
- [6]. Prasad KD, Hegde C, Alva H, Shetty M. Medical and dental emergencies and complications in dental practice and its management. *Journal of Education and Ethics in Dentistry*. 2012 Jan 1;2(1):13.
- [7]. *Burket's Textbook of oral medicine-12th edition*.
- [8]. Steinbacher DM, Glick M. The dental patient with asthma. An update and oral health considerations. *J Am Dent Assoc*. 2001 Sep;132(9):1229-39. PubMed PMID: 11665347.
- [9]. Claramunt Lozano A, Sarrión Pérez MG, Gavaldá Esteve C. Dental considerations in patients with respiratory problems.
- [10]. Malik S, Singh G. deNtal MaNaGeMeNt OF diaBetiC PatieNtS: a CliNi-Cal RevieW. *International Arab Journal of Dentistry*. 2014 Feb 14;5(1).
- [11]. Aragon CE, Burneo JG. Understanding the patient with epilepsy and seizures in the dental practice. *J Can Dent Assoc*. 2007 Feb;73(1):71-6. PubMed PMID: 17295949.
- [12]. Continue CP. AAGBI Safety Guidelines.
- [13]. Reed KL. Basic management of medical emergencies: recognizing a patient's distress. *J Am Dent Assoc*. 2010 May;141 Suppl 1:20S-4S. PubMed PMID: 20436086.
- [14]. Thyssen JP, Menné T, Elberling J, Plaschke P, Johansen JD. Hypersensitivity to local anaesthetics--update and proposal of evaluation algorithm. *Contact Dermatitis*. 2008 Aug;59(2):69-78. PubMed PMID: 18759873.
- [15]. Reber LL, Hernandez JD, Galli SJ. The pathophysiology of anaphylaxis. *J Allergy Clin Immunol*. 2017 Aug;140(2):335-348. PubMed PMID: 28780941.
- [16]. *Textbook of physiology Ak jain, 2nd edition*.
- [17]. Samulak-Zielińska R, Dembowska E, Lizakowski P. Dental treatment of post-myocardial infarction patients: A review of the literature. *Dent Med Probl*. 2019 Jul-Sep;56(3):291-298. PubMed PMID: 31577073.
- [18]. Kurien S, Kattimani VS, Sriram RR, Sriram SK, Rao V K P, Bhupathi A, et al. Management of pregnant patient in dentistry. *J Int Oral Health*. 2013 Feb;5(1):88-97. PubMed PMID: 24155583.
- [19]. Giglio JA, Lanni SM, Laskin DM, Giglio NW. Oral health care for the pregnant patient. *J Can Dent Assoc*. 2009 Feb;75(1):43-8. PubMed PMID: 19239743.
- [20]. Silk H, Douglass AB, Douglass JM, Silk L. Oral health during pregnancy. *Am Fam Physician*. 2008 Apr 15;77(8):1139-44. PubMed PMID: 18481562.
- [21]. Dinkova A, Kirova DG, Delev D. Dental management and bleeding complications of patients on long-term oral antiplatelet therapy. Review of existing studies and guidelines. *Journal of IMAB--Annual Proceeding Scientific Papers*. 2013 Jun 4;19(2):298-304.
- [22]. McCord C, Johnson L. Oral Manifestations of Hematologic. *Oral Manifestations of Systemic Diseases, an Issue of Atlas of the Oral & Maxillofacial Surgery Clinics, E-Book*. 2017 Aug 17;25(2):149.
- [23]. Adeyemo TA, Adeyemo WL, Adediran A, Akinbami AJ, Akanmu AS. Orofacial manifestations of hematological disorders: anemia and hemostatic disorders. *Indian J Dent Res*. 2011 May-Jun;22(3):454-61. PubMed PMID: 22048588.