

Endoscopic Assessment of Aditus in Sclerosed Mastoid

Research Article

Alaa Mohamed Abdel Samie*, Ayman Abdelaal Mohamady

Otorhinolaryngology department, Faculty of Medicine, Benha university, Egypt.

Abstract

Object: To determine outcomes of endoscopic assessment of the Aditus Patency in Mucosal COM with Sclerosed Mastoid during tympanoplasty.

Methods: 50 patients presenting with inactive tubo-tympanic CSOM with sclerosed mastoid. Antrotomy with tympanoplasty were done for all patients. The intraoperative patency of the aditus was assessed by microscope and 30° Error! Not a valid embedded object. otoendoscope.

Results: 20 (80%) patients of endoscopic group compared to 10 (40%) patients in microscopic group showed graft take with statistically significant difference ($p = 0.025$).

Conclusion: Otoendoscopy is a minimally invasive surgery and could be utilized efficiently to improve the visibility of aditus and then dealing with any pathology in mucosal COM with sclerosed mastoid during tympanoplasty.

Summary at glance: 50 patients presenting with inactive tubo-tympanic CSOM with sclerosed mastoid. The intraoperative patency of the aditus was assessed by microscope and 30° otoendoscope during tympanoplasty.

Keywords: Aditus; Endoscopic; Sclerosed.

Introduction

Chronic otitis media (COM) is one of the most common problems in otology, which leads to permanent changes in the tympanic membrane and/or in the structures of the middle ear [1]. It is further classified as non-cholesteatomatous and cholesteatomatous [2]. Aditus ad antrum plays an important role in ventilation of mastoid air cell system. Aeration of middle ear results through two pathways: via the Eustachian tube and the tympanic isthmus. The aeration pathway from the Eustachian tube directly leads to the mesotympanic and hypotympanic spaces, whereas the epitympanum is away from direct air stream and is only aerated through the tympanic isthmus. Tympanic isthmus is located between the medial part of the posterior incudal ligament and the tensor tendon [3, 5]. The lack of an aerated mastoid at the time of tympanoplasty may be a significant source of failure in mucosal chronic otitis media (COM) with sclerosed mastoid. To see the patency of aditus ad antrum intra-operatively antrotomy is performed [3, 5].

Up Till now, there are no strict guidelines when to perform antrotomy in dry perforation in inactive mucosal COM with sclerosed

mastoid [6]. Antrotomy is not necessary for successful repair of central perforation. However, adding an antrotomy to tympanoplasty improves clinical results, because of increased volume and pressure buffer created by open mastoid cavity [6].

The use of the endoscope is rapidly increasing in otological and neuro-otological surgery in the last 2 decades. Middle ear surgeries, including tympanoplasty, have increasingly utilized endoscopes as an adjunct to or as a replacement for the operative microscope. Superior visualization and transcanal access to diseases normally managed with the transmastoid approach are touted as advantages of the endoscope [7].

The present study aimed to compare the outcomes of endoscopic and microscopic assessment of the Aditus Patency in Mucosal COM with Sclerosed Mastoid during tympanoplasty.

Materials and Methods

This prospective clinical study was conducted on 50 patients at Benha University hospital, Faculty of medicine, ENT department

*Corresponding Author:

Alaa Mohamed Abdel Samie,
Otorhinolaryngology department, Faculty of Medicine, Benha university, Egypt.
Tel: 01114015115
E-mail: alaasalma123.am@gmail.com

Received: August 13, 2020

Accepted: September 08, 2020

Published: September 11, 2020

Citation: Alaa Mohamed Abdel Samie, Ayman Abdelaal Mohamady. Endoscopic Assessment of Aditus in Sclerosed Mastoid. *Int J Clin Exp Otolaryngol.* 2020;6(4):117-121.
doi: <http://dx.doi.org/10.19070/2572-732X-2000022>

Copyright: Alaa Mohamed Abdel Samie©2020. This is an open-access article distributed under the terms of the Creative Commons Attribution License, which permits unrestricted use, distribution and reproduction in any medium, provided the original author and source are credited.

ment, from May 2019 to March 2020. Patients were randomly divided into two groups; group A, 25 patients were assessed endoscopically, and group B, 25 patients were assessed microscopically.

2.1.1. All patients underwent detailed history taking, clinical examination, full audiological evaluation and high-resolution computed tomography (HRCT) temporal bone.

2.1.2. Inclusion criteria

The patients who were diagnosed as mucosal COM with sclerosed mastoid on radiograph with only mild or moderate conductive hearing loss were included in the study.

2.1.3. Exclusion criteria

Patients with previous ear surgery or with severe conductive or mixed hearing loss were excluded.

Local ethical committee approval and informed consent were taken before the onset of the study.

2.1.4. Surgical procedure

All patients underwent tympanoplasty through post auricular approach and antral window was drilled.

2.1.4.1 Intraoperative Assessment of Aditus Patency by endoscope: After antrotomy, the 30° endoscope was inserted through the antral window to assess the patency and of aditus. The tympanosclerosis, granulations and diseased mucosa in the aditus were assessed.

2.1.4.2 Intraoperative Assessment of Aditus Patency by operating microscope: the patency of aditus was assessed by operating microscope in different positions. The visible anatomical areas were evaluated by performing gentle.

Maneuvers on the patients head.

2.1.4.3. Intraoperative normal saline solution was instilled into the antrum with 10 ml syringe to test whether there was free communication between the antrum and middle ear in both groups. If there was free flow; test result was considered positive and there was no need for further exposure of the epitympanum. If the water test result was negative, the bony posterior metal wall was thinned until short process of the incus was identified, then, the soft tissue in the region of aditus ad antrum was removed and dissected until saline pass to the middle ear. Re-establishment of the patency of attic may require removal of pathological mucosa surrounding the ossicles and sometimes even removal of incus. Gel foam was applied to middle ear. Insertion of the temporalis fascia graft underlay followed by insertion of gel foam in the middle ear were performed. Post auricular incision was closed in layers with interrupted sutures with packing the external auditory canal.

2.1.5. Follow up and outcome

All patients had a postoperative systemic antibiotic treatment for 2 weeks, otological examination were done at 3 and 6 months postoperatively.

Statistical analysis

The recruitment for the study started from May 2019 and was completed by March 2020 once the requisite numbers of the patients. The collected data were summarized in terms of mean + standard Deviation (SD) and range for quantitative data and frequency and percentage for qualitative data. Comparisons between the different study groups were carried out using the test of proportion (Z-test) to compare two proportions and the Chi-square test and Fisher exact test were used to compare more than two proportions as appropriate. The Mann-Whitney test was used to detect differences between two groups regarding non-parametric data. Statistical significance was accepted at $P < 0.05$. The statistical analysis was conducted using STATA/SE 11.2 for Windows (STATA Corporation, College Station, Texas).

Results

Of the 50 patients in this study, 27 were male (54%) and 23 were female (46%). The mean age of the patients was 31.12 years, with a range of 18–50 years (Table 1).

Out of the 50 cases, 15 cases (60%) in endoscopic group and 13 cases (52%) in microscopic group had blocked aditus with unhealthy mucosa. In the other hand, 22 cases (44%) had patent aditus with a healthy mucous membrane lining. No hidden cholesteatoma was detected in both groups.

The site of tympanic membrane perforation was assessed. In 50 cases, the perforation was anterior in 40% of the endoscopic group and 68% of microscopic group, it was posterior in two cases (8%) of both groups and subtotal in 52% and 24% of endoscopic and microscopic group, respectively.

Regarding ear discharge, it was more than 3 years in 14 cases of the endoscopic group and 10 cases in microscopic one. In contrast, it was less than 3 years in 11 cases in endoscopic group and 15 cases in the other one.

The age range of the blocked-aditus patients was 40–50 years with a mean of 45.2 ± 3.24 years and a median of 40 years. In contrast, the patent aditus occurred in a younger age population, the mean age was 25 ± 6.44 years and the median was 30 years. There was a significant relation between the age and the status of the aditus on statistical analysis. The incidence of obstructed aditus increased in the elderly patients.

Regarding the site of perforation and its relation to the aditus patency, the incidence of blocked aditus was higher in subtotal and posterior perforation cases. 13 (68.42%) out of 19 subtotal perforation cases were associated with blocked aditus. The four posterior perforation patients were associated with blocked aditus (100%). However, out of the 27 anterior perforation cases, 4 (14.8%) cases were associated with obstructed aditus and 23 (85.18%) cases with patent aditus.

Regarding ear discharge, 24 out of 28 (85.7%) patients with blocked aditus had a long history of otorrhea. We had reported a significant relation between the history of ear discharge and the aditus status.

Endoscopic assessment showed a detailed view about the aditus status despite of saline test which was positive (free flow) in 15 cases in only 10 patent aditus in endoscopic group. In which, Two out of five cases had edematous mucosa and the remaining 3 cases had minimal granulations [Figure 1]. So, the saline test may show a false impression of aditus patency despite of its obstruction. In the other hand, saline test was positive in all cases of pat-

ent aditus in microscopic group.

Regarding the success rate, 20 (80%) patients of endoscopic group compared to 10 (40%) patients in microscopic group showed graft take [Figure 2] with statistically significant difference ($p = 0.025$) (Table 2) at 6 months follow up.

Table 1. Demographic data and clinical characteristics.

Demographic data	ENDOSCOPIC GROUP (n=25) N (%)	MICROSCOPIC GROUP (n=25) N (%)
Age group (years)		
18-25	11(44)	10(40)
26-40	8(32)	7(28)
41-60	6(24)	8(32)
sex		
male	13(52)	14(56)
Female	12(48)	11(44)
ASSESSMENT OF ADITUS STATUS		
patent +VE	10(40)	12(48)
-VE	15(60)	13(52)
Polyp	7(28)	5(20)
Granulation	5(20)	5(20)
Edema	3(12)	3(12)
Hidden chloestatoma	0(0)	0(0)
T.M perforation		
anterior	10(40)	17(68)
Post	2(8)	2(8)
subtotal	13(52)	6(24)
Duration of ear discharge		
more than3 years	14(56)	10(40)
less than 3 year	11(44)	15(60)

Figure 1. Endoscopic view of granulation tissue in the aditus ad antrum.

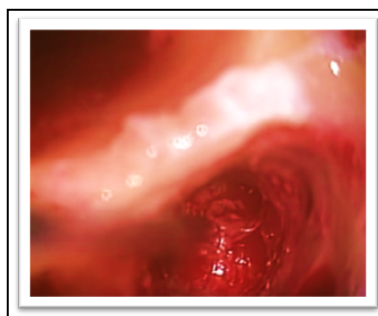


Figure 2. Graft uptake after 3 months follow up.

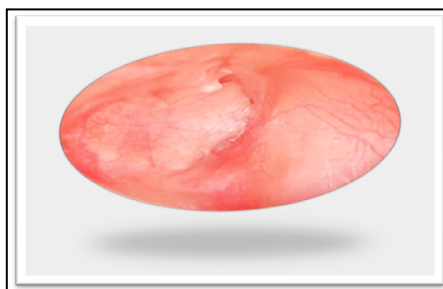


Table 2. Success rate of endoscopic and microscopic group.

Success Rate	Endoscopic (no=25)		Microscopic (no=25)		P*
	No.	%	No.	%	
Graft Take	20	80	10	40	0.025 (s)
Graft Failure	5	20	15	60	

Discussion

Holmquist and Bergstrom [8] first suggested that mastoidectomy improves the chance of successful tympanoplasty for patients with non cholesteatomatous CSOM. They argued that creation of an aerated mastoid enhances success in patients with poor tubal function or a small mastoid air cell system. Several authors supported the theory proposed by Holmquist and Bergstrom [8].

Ruhl and Pensak [9] opined that mastoidectomy should only be considered in all failed cases of tympanoplasty reconstruction and also if the preoperative imaging showed poorly pneumatized mastoid, or in those with evidence of soft tissue in the mastoid, aditus, or epitympanum.

Tympanomastoidectomy, which was traditionally performed using a microscope, is currently being performed using an endoscope [10]. Although, the microscope is considered as the gold standard for the otological procedures, as it provides stereoscopic vision, better depth perception, and bimanual handling [11], Several studies have already proven that the endoscope significantly reduces the operative time due to the lack of necessity to see the recesses, to its wide vision, and to the lack of necessity to perform postoperative suturing.

The endoscope has been now rapidly used for tympanoplasty since the first article published by el-Guindy in 1992 [12].

This has helped patients to have a fast recovery, a shorter hospital stay, and a lower financial burden, which is especially helpful for developing countries like ours. Newer high-definition cameras have provided better image quality to access blind sacs, middle ear spaces that would be impossible to be visible by microscope [13]. The present study aimed to compare the outcomes of endoscopic and microscopic assessment of the Aditus Patency in Mucosal COM with Sclerosed Mastoid during tympanoplasty.

Albu et al., reported that presence of congested and polypoidal mucosa in the middle ear may not be associated with blocked aditus and antrum [14, 15]. This concedes with our study in which endoscopic assessment showed a detailed view about the aditus status despite of saline test which was positive (free flow) in 15 cases in only 10 patent aditus in endoscopic group. In which, Two out of five cases had edematous mucosa and the remaining 3 cases had minimal granulations. So, the saline test may show a false impression of aditus patency despite of its obstruction.

In the other hand, saline test was positive in all cases of patent aditus in microscopic group.

So, endoscopic assessment has reflections in our study results which showed the graft uptake in both endoscopic and micro-

scopic group was 20/10 at the 6-month follow-up with statistical differences between the 2 groups ($p=0.025$).

A study performed by Choi et al that compared endoscopic and microscopic tympanoplasty had 100% graft uptake in the endoscopic group ($n=25$) and 95.8% ($n=48$) in the microscopic group, which was not statistically significant ($p=0.304$), with a mean follow-up of 6.4 months (range: 3–11 months) [16]. Another study, performed in 2017 by Jyothi et al., compared microscopic with endoscopic myringoplasty, with 60 cases in each group. They had and uptake rate of 91.67% in the endoscopic group and of 93.3% in the microscopic group at 1 year of follow-up [17].

There are also limitations to endoscopic ear surgery as it is a one-handed surgery and there is lack of depth perception. Both of these limitations can be overcome by experience and practice.

Conclusion

Otoendoscopy is a minimally invasive surgery and could be utilized efficiently to improve the visibility of aditus and then dealing with any pathology in mucosal COM with sclerosed mastoid during tympanoplasty.

References

- [1]. Cabra J, Moñux A. Efficacy of cartilage palisade tympanoplasty: randomized controlled trial. *Otol Neurotol*. 2010; 31(4): 589-595. PMID: 20418792.
- [2]. Fukuchi I, Cerchiari DP, Garcia E, Rezende CE, Rapoport PB. Tympanoplasty: surgical results and a comparison of the factors that may interfere in their success. *Bras Otorrinolaringol*. 2006; 72(02): 267-271. PMID: 16951864.
- [3]. Palva T, Ramsay H. Incudal folds and epitympanic aeration. *Am J Otol*. 1996; 17(5): 700-708. PMID: 8892564.
- [4]. Marchioni D, Molteni G, Presutti L. Endoscopic anatomy of the middle ear. *Ind J Otolaryngol Head Neck Surg*. 2011; 63(2): 101-113. PMID: 22468244.
- [5]. Marchioni D, Alicandri-Ciuffelli M, Molteni G, Artioli FL, Genovese E, Presutti L. Selective epitympanic dysventilation syndrome. *Laryngoscope* 2010; 120(5):1028-1033. PMID: 20422699.
- [6]. Hamada Y, Utahashi H, Aoki K. Physiological gas exchange in the middle ear cavity. *Int J Pediatr Otorhinolaryngol*. 2002; 64: 41-49. PMID: 12020913.
- [7]. Yadav SP, Aggarwal N, Julaha M, Goel A. Endoscope-assisted myringoplasty. *Singapore Med J*. 2009; 50(5): 510-512. PMID: 19495522.
- [8]. Holmquist J, Bergstrom B. The mastoid air cell system in ear surgery. *Arch Otolaryngol*. 1978; 104: 127-129. PMID: 629709.
- [9]. Ruhl CM, Pensak ML. Role of aerating mastoidectomy in non cholesteatomatous chronic otitis media. *Laryngoscope* 1999; 109: 1924-1927. PMID: 10591348.
- [10]. Bedajit RK, Mallik P, Kumar P, et al. Endoscopic transcanal mastoidectomy with tympanoplasty. *Natl J Otorhinolaryngol Head Neck Surg*. 2015; 3(12): 10-11.
- [11]. Kanona H, Virk JS, Owa A. Endoscopic ear surgery: A case series and first United Kingdom experience. *World J Clin Cases*. 2015; 3(3): 310-317. PMID: 25789304.
- [12]. el-Guindy A. Endoscopic transcanal myringoplasty. *J Laryngol Otol*. 1992; 106(6): 493-495. PMID: 1624881.
- [13]. Huang TY, Ho KY, Wang LF, Chien CY, Wang HM. A Comparative Study

- of Endoscopic and Microscopic Approach Type 1 Tympanoplasty for Simple Chronic Otitis Media. *J Int Adv Otol.* 2016; 12(1): 28-31. PMID: 27340979.
- [14]. Albu S, Tralazini F, Amadori M. Usefulness of cortical mastoidectomy in myringoplasty. *OtolNeurotol.* 2012; 33: 604-609. PMID: 22588236.
- [15]. Vijayendra H, Mahadevaiah A, Surendran K, Sangeetha R. Micro ear surgery - its purpose and procedure for tubotympanic pathology. *Indian J Otolaryngol Head Neck Surg.* 2005; 57(4): 360-363. PMID: 23120223.
- [16]. Choi N, Noh Y, Park W, Jung Joo Lee, Sunhyun Yook, Ji Eun Choi, et al. Comparison of endoscopic tympanoplasty to microscopic tympanoplasty. *Clin Exp Otorhinolaryngol.* 2017; 10(1): 44-49. PMID: 27334511.
- [17]. Jyothi AC, Shrikrishna BH, Kulkarni NH, Kumar A. Endoscopic Myringoplasty Versus Microscopic Myringoplasty in Tubotympanic CSOM: A Comparative Study of 20 Cases. *Indian J Otolaryngol Head Neck Surg.* 2017; 69(3): 357-362. PMID: 28929068.