

## Anesthetic Management of Hemophilia C in a Patient with Recurrent Intra-abdominal and Retroperitoneal Liposarcoma using ROTEM®

Case Report

William J. Beeston\*, Alix Zuleta-Alarcon, Ritu Kapoor, Agbenyefia Priscilla, Antolin S. Flores

Department of Anesthesiology, The Ohio State University Wexner Medical Center, Columbus, Ohio, USA.

### Abstract

Intraoperative coagulopathies can be complex and difficult to treat. Its management is further obfuscated in patients with pre-existing bleeding disorders. Hemophilia C, is an autosomal recessive bleeding disorder. Like in most hemophilias, the bleeding tendency is variable depending on the activity level of factor XI. However, because hemophilia C is less common than other coagulopathies, it is usually recognized only after inappropriate bleeding often overcorrected with blood products, exposing the patient to further risks. The purpose of this report is to describe the role of rotational thromboelastometry in the anesthetic management of a patient with hemophilia C undergoing debulking of a recurrent intra-abdominal and retroperitoneal liposarcoma.

**Keywords:** Factor XI Deficiency; Hemophilia C; ROTEM; Intraoperative Bleeding.

### \*Corresponding Author:

William J. Beeston, D.O,  
Department of Anesthesiology, The Ohio State University Wexner Medical Center, 410 West 10<sup>th</sup> Avenue, Columbus, Ohio 43210, USA.  
Tel: 614-600-0161  
E-mail: william.j.beeston@gmail.com

**Received:** September 26, 2015

**Accepted:** October 21, 2015

**Published:** October 28, 2015

**Citation:** William J. Beeston, et al., (2015) Anesthetic Management of Hemophilia C in a Patient with Recurrent Intra-abdominal and Retroperitoneal Liposarcoma using ROTEM®. *Int J Anesth Res.* 3(9), 162-165.  
**doi:** <http://dx.doi.org/10.19070/2332-2780-1500040>

**Copyright:** William J. Beeston® 2015. This is an open-access article distributed under the terms of the Creative Commons Attribution License, which permits unrestricted use, distribution and reproduction in any medium, provided the original author and source are credited.

### Introduction

Hemophilia C, or factor XI deficiency, is an autosomal recessive bleeding disorder first described by Rosenthal and Colleagues in 1953 [1]. It has an estimated incidence of 1 per 1,000,000 persons overall, but is more common in the Ashkenazi Jewish population, with a heterozygotic frequency of approximately 9% [2, 3]. Severe Factor XI deficiency is defined as a factor XI activity level of less than 15% of normal [4]. Partial deficiency is defined as a factor XI activity level from 20 to 70% [4]. Although it is assumed medically that the severity of bleeding in patients with Hemophilia C is directly related to the activity level of factor XI, this is not always the case as serum factor XI levels do not correlate well to the severity and likelihood of bleeding [5, 6]. It has been shown that 20-50% of patients with partial factor XI deficiency bleed excessively after a surgery [6].

Factor XI is essential for the formation and maintenance of co-

agulation. It performs this role by amplifying the initial coagulation response via a positive feedback mechanism, generating additional thrombin. In the intrinsic pathway, factor XII activates factor XI, which in turn activates factor IX [7-10]. Factor IX then activates factor X (thrombin) which goes on to convert factor II (fibrinogen) to fibrin for clot stabilization. In the tissue factor (extrinsic) pathway of coagulation, it is factor VII that converts prothrombin to thrombin. In both cases, activation of thrombin has a positive effect on the activation of factor XI, leading to thrombin burst and the propagation and maintenance of coagulation [7-10]. Factor XI also aids in the formation of fibrin and prevents fibrinolysis by activating thrombin-activatable fibrinolytic inhibitor (TAFI) [7-10].

The activation of this hemostatic process by vascular injury and bleeding can be rapidly assessed by point of care rotational thromboelastometry (ROTEM®; TEM International GmbH, Munich, Germany). In this case, we show how ROTEM® can be used to tailor therapy to a patient's coagulation status in near real-time minimizing both the risk of uncontrolled bleeding and the excessive use of blood products. Patient's verbal informed consent was obtained to publish this case report. In addition, our local IRB states that Case Reports do not require IRB approval.

### Case Report

A 69-year-old Caucasian male with a large recurrent intra-abdominal and retroperitoneal liposarcoma presented for debulking. He was first diagnosed in 1993 and had undergone several rounds of chemotherapy followed by multiple surgical debridements. During one of his operations, he developed uncontrolled bleeding and required activation of the massive transfusion protocol. Subsequent hematologic studies revealed the cause of his bleeding to be factor XI deficiency.

Past medical history was significant for hypertension, easy bruising,

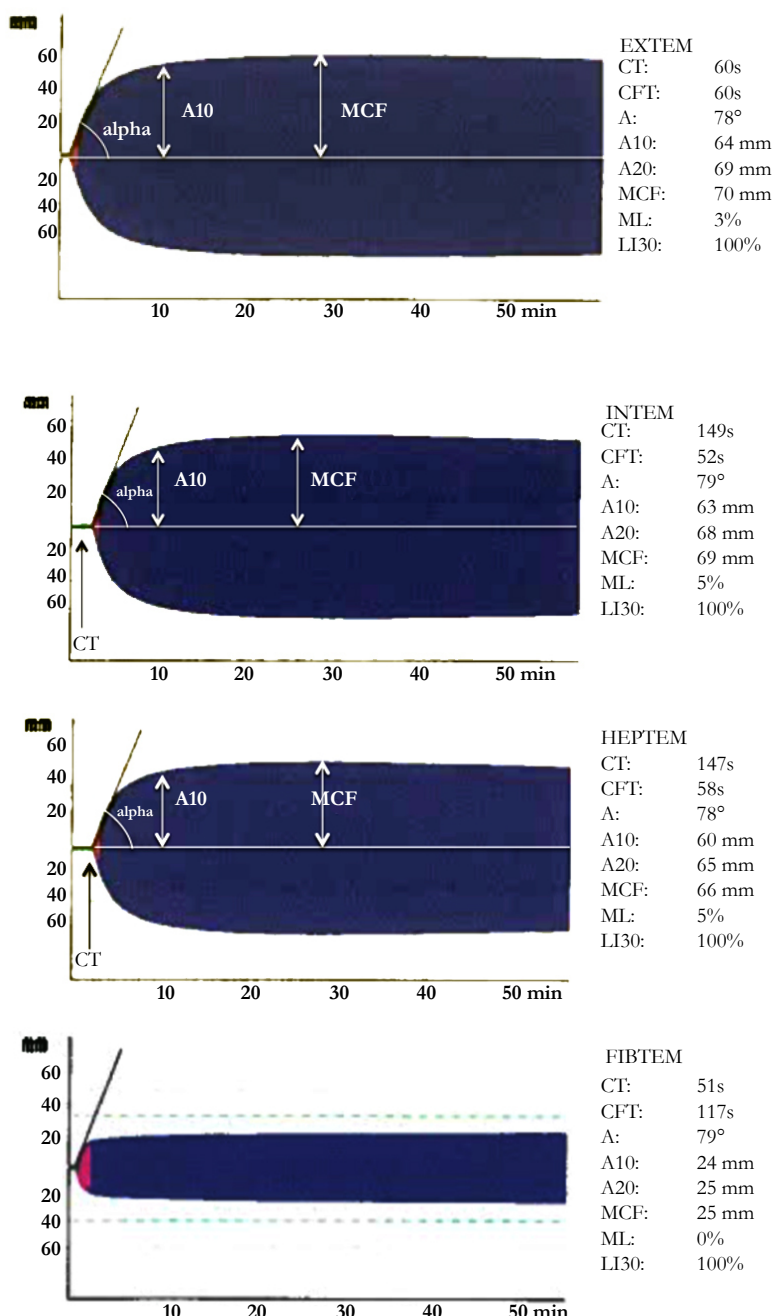
ing and bleeding, including spontaneous epistaxis that required blood transfusions and hemostasis by an ear, nose and throat specialist. Family history was negative for bleeding tendencies or hemophilia. Preoperative laboratory tests revealed a factor XI assay of 45%; international normalized ratio (INR) 1.3, partial thromboplastin time (PTT) 43 seconds, fibrinogen 396 mg/dL, and a platelet count of 150 K/uL. Hemoglobin was 10.2 g/dl. Previous operations had been accomplished without bleeding complications when the preoperative factor XI assay was 30% by administering 6 units of fresh frozen plasma (FFP) preoperatively, followed by 2 units of FFP daily for 3 days.

On the morning of surgery, the patient was given 3 units of FFP preoperatively based on an evidence-based calculation by a hematology consultant of the estimated dose required to provide sufficient factor XI activity to restore acceptable coagulation. His

vital signs included a blood pressure of 149/87, heart rate 63, respirations 16 and oxygen saturation 100% on room air. The blood pressure was monitored using an arterial line. Electrocardiography, pulse oximetry, central venous pressure and nasopharyngeal temperature were monitored intraoperatively.

The patient was preoxygenated followed by a rapid sequence induction using fentanyl 100 mcg, lidocaine 100 mg, propofol 200 mg, and succinylcholine 160 mg. Anesthesia was maintained with sevoflurane (1.0-2.0%), vecuronium, and a 50% oxygen/air mixture. During the operation the patient became hypotensive and was noted by the surgeon to show signs of increased surgical bleeding. In order to provide better goal-directed therapy a ROTEM<sup>®</sup> assay was performed with results in Figure 1. Total operative time was 5 hours and 30 minutes. Intraoperative blood loss was 300 ml. Intraoperative hypotension was corrected with a phe-

**Figure 1. Results of ROTEM<sup>®</sup>, the tracings shown above are EXTEM, INTEM and FIBTEM. The CT of the EXTEM and INTEM tracings show that clot formation begins quickly. The alpha angle (EXTEM) shows that once the coagulation begins the clot forms quickly and the MCF (EXTEM and FIBTEM) demonstrates strong clot strength. CT, denotes clotting time; CFT, clot formation time; alpha, alpha angle; A10, amplitude 10 minutes after clotting time; A20, amplitude 20 minutes after clotting time; MCF, maximum clot firmness; ML, maximum lysis; LI30, lysis index 30 minutes after clotting time.**



nylephrine infusion. No blood products were administered intraoperatively. The decision to administer FFP postoperatively was based on patient evaluation for signs of bleeding such as pallor, fatigue, tachycardia, and surgical site bleeding, and by following the hemoglobin. On postoperative day 1 (POD1), hematocrit was stable at 30 % with no signs of bleeding and therefore no FFP was administered. On POD2, there was some mild oozing at the surgical site, and 1 unit of FFP was given. On POD3 hematocrit was still 30% with no sign of bleeding. The patient was discharged on POD10 with no additional need for administration of FFP.

**Discussion**

Prophylactic treatment options for factor XI deficiency patients undergoing surgery include factor XI concentrate, FFP, antifibrinolytic agents, desmopressin and recombinant factor VIIa. Since factor XI concentrate is not available in the United States, the most common method for prophylaxis and treatment of factor XI deficiency is administration of FFP. Some authorities suggest a prophylactic loading dose of 10-20 ml/kg prior to surgery followed by 5-10 ml/kg every day for up to 7 days after surgery [12-14]. Duga and Salomon suggest a goal of 40% for factor XI activity trough for one week [15]. However, significant bleeding is sometimes seen even at these levels [13].

The difficult risk-benefit analysis of perioperative FFP transfusion in patients with coagulopathies has prompted the development of new methods for intraoperative measurement of coagulation parameters. Conventional coagulation test are unreliable in predicting the occurrence of intraoperative bleeding. An additional problem with tests is the long processing time, makes their intraoperative use impractical.

ROTEM® is a point-of-care coagulation assay that was developed to address these shortcomings (Figure 2) [16]. Based on the measurement of the viscoelastic properties of clot formation in whole blood (conventional tests use platelet-poor plasma), the ROTEM® assay reveals a wealth of information about a patient's coagulation status, and has the ability to discriminate between coagulopathies caused by factor deficiencies and those caused by platelet abnormalities. While ROTEM® has been approved in several European countries since 2003, it was not approved by the FDA until 2011, and many US hospitals have yet to adopt this technology [17-20].

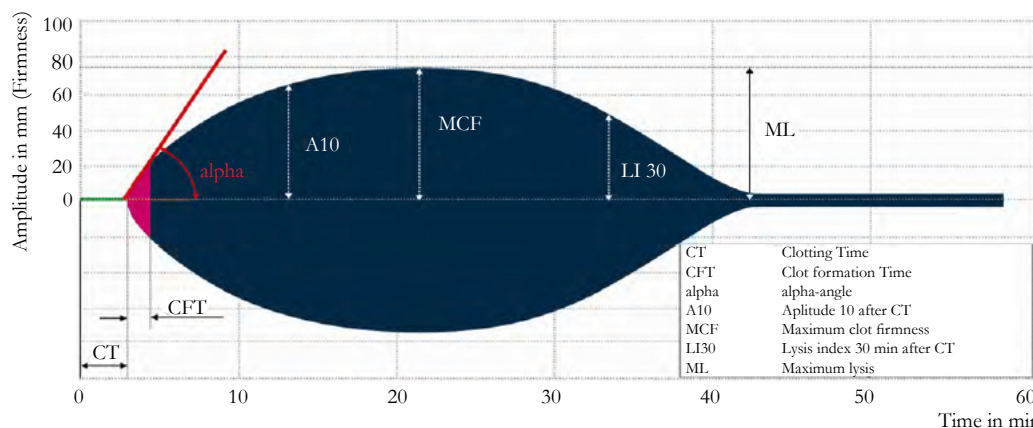
In this case ROTEM allowed an optimal thrombosis assessment in a patient at risk of cancer-associated thrombosis. In this population thrombosis represent the second cause of dead after can-

cer. In general, in patients with cancer the tumor can provoke venous stasis and decrease coagulation factors circulation due to direct vascular compression and patient immobility. In addition, activation of the coagulation cascade can be triggered by inflammatory cells, cytokines, endothelium disruption, laminar blood flow disturbance by direct vascular invasion, tumor cells procoagulant, and tissue factor expression [21]. Furthermore, surgery itself could also alter the components of the Virchow's triad and predispose our patient to venous thromboembolism [21].

During this case, intraoperative coagulation monitoring with ROTEM® allowed us to avoid unnecessary further use of blood products. Because FFP does not contain concentrated levels of factor XI, large amounts of FFP are often required in the treatment of Hemophilia C which is associated with the risk of several adverse events such fluid overload, infection, transfusion reactions including transfusion-related acute lung injury (TRALI), and anaphylaxis [22-24]. Fluid overload correlates with volume and rate of infusion, positive fluid balance, and can be present in up 1-8% of transfusions [22, 23]. TRALI, is thought to be associated to granulocytic-specific antibodies, HLA, and FFP from female donors. This lung injury is characterized by rapid onset pulmonary edema, hypoxemia, and dyspnea in the absence of circulatory overload and is one of the leading causes of mortality associated with transfusion [23]. In contrast to TRALI, most of allergic transfusion reactions are mild consisting in flushing, urticaria, and pruritus. However up to 1:18,000 transfusions can present with systemic symptoms [23]. It is worth to note the potential of ROTEM in the prevention of inappropriate transfusions in patients with coagulopathies such as hemophilia, that otherwise could lead to the aforementioned transfusion-related adverse events. In addition, thromboelastometry could be considered in the monitoring of hemostatic performance after recombinant factors administration in patients with hemophilia A and B with neutralizing antibodies against exogenous factors [25].

In previous cases without intraoperative monitoring, this patient had received considerable volumes of perioperative FFP based on preoperative factor XI activity assays. We wished to minimize the patient's FFP exposure during this procedure, and antifibrinolytics were relatively contraindicated due to the increased risk of venous thromboembolic events (VTEs) in malignancy. The administration of 3 units of FFP preoperatively, rather than 6 as had been done previously, was based on an evidence-based calculation by the hematology consultant of the estimated dose required to provide sufficient factor XI activity to restore acceptable coagulation.

**Figure 2. Rotational Thromboelastometry (ROTEM) provides information about the coagulation kinetics.**





When the patient developed intraoperative hypotension, ROTEM® was performed to assess coagulation status and evaluate the need for administration of blood products. The technical details of ROTEM® are described elsewhere [18]. In our case (See Figure 1), the CT and alpha-angle were at the upper limits of normal in both INTEM and EXTEM. The FIBTEM assay, which assesses the stability of a clot based on the presence of fibrin and factor XIII levels in the blood sample was elevated, an expected result given this patient's known history of malignancy. With a known factor XI deficiency, we expected the patient's INTEM to be prolonged due to the presumed absence of adequate amounts of factor XI to aid in propagation of the coagulation cascade, and hence clot formation. For instance, over a threefold prolongation of CT in INTEM was reported in a patient with homozygous severe factor XI deficiency [11]. The abnormal FIBTEM assay was more significant in our case as malignancy can lead to a hypercoagulable state. Based on the information from the ROTEM® it was thus determined that the patient was not hypocoagulable, but was relatively hypercoagulable. Intraoperative administration of FFP was therefore not required. The administration of additional FFP would have increased fibrin clot formation further and increased our patient's risk for VTEs given his risk factors of malignancy, epithelial damage from surgery, and venous stasis from his sedentary post-surgical state.

### Conclusion

The use of ROTEM® as a point-of-care coagulation assay to direct the perioperative management of patients at risk for intraoperative bleeding proved very valuable in our case. Although severe intraoperative and postoperative hemorrhage can increase morbidity and mortality among patients, excessive transfusion of blood products can lead to complications. As such, a thorough understanding of hemostasis and its intraoperative management is essential to prevent unnecessary transfusion. ROTEM® can be used to safely and confidently tailor therapy to a patient's coagulation status in near real-time, minimizing both the risk of uncontrolled bleeding and the excessive use of blood products. In our case, it was established that our patient with a known deficiency in factor XI requiring massive transfusions of FFP in past surgeries was actually hypercoagulable, making the use of intraoperative FFP unnecessary during the debulking of his liposarcoma.

### References

- [1]. Rosenthal RL, Dreskin OH, Rosenthal N (1953) New hemophilia-like disease caused by deficiency of third plasma thromboplastin factor. *Proc Soc Exp Biol Med* 82(1): 171-174.
- [2]. Seligsohn U (2009) Factor XI deficiency in humans. *J Thromb Haemost* 7(Suppl 1): 84-87.
- [3]. Shpilberg O, Peretz H, Zivelin A, Yatuv R, Chetrit A, et al. (1995) One of

- the two common mutations causing factor XI deficiency in Ashkenazi Jews (type II) is also prevalent in Iraqi Jews, who represent the ancient gene pool of Jews. *Blood* 85(2): 429-432.
- [4]. Bolton-Maggs PH, Patterson DA, Wensley RT, Tuddenham E (1995) Definition of the bleeding tendency in factor XI-deficient kindreds--a clinical and laboratory study. *Thromb Haemost* 73(2): 194-202.
- [5]. Salomon O, Steinberg DM, Seligshon U (2006) Variable bleeding manifestations characterize different types of surgery in patients with severe factor XI deficiency enabling parsimonious use of replacement therapy. *Haemophilia* 12(5): 490-493.
- [6]. Ragni MV, Sinha D, Seaman F, Lewis JH, Spero JA, et al. (1985) Comparison of bleeding tendency, factor XI coagulant activity, and factor XI antigen in 25 factor XI-deficient kindreds. *Blood* 65(3): 719-724.
- [7]. Bolton-Maggs PH (1999) Bleeding problems in factor XI deficient women. *Haemophilia* 5(3): 155-159.
- [8]. Kadir RA, Economides DL, Lee CA (1999) Factor XI deficiency in women. *Am J Hematol* 60(1): 48-54.
- [9]. Bouma BN, Meijers JCM (1999) Fibrinolysis and the contact system: A role for factor XI in the down-regulation of fibrinolysis. *Thromb Haemost* 82(2): 243-250.
- [10]. Von Dem Borne PA, Bajzar L, Meijers JCM, Nesheim ME, Bouma BN (1997) Thrombin-mediated activation of factor XI results in a thrombin-activatable fibrinolysis inhibitor-dependent inhibition of fibrinolysis. *J Clin Invest* 99(10): 2323-2327.
- [11]. Dirkmann D, Hanke AA, Görlinger K, Peters J (2007) Perioperative use of modified thrombelastography in factor XI deficiency: A helpful method to assess drug effects. *Acta Anaesthesiol Scand* 51(5): 640-643.
- [12]. Kim SH, Srinivas SK, Rubin SC, Freedman LJ, Gray HJ (2004) Delayed hemorrhage after cervical conization unmasking severe factor XI deficiency. *Obstet Gynecol* 104(5 Pt 2): 1189-1192.
- [13]. Steinberg MH, Saletan S, Funt M, Baker D, Coller BS (1986) Management of factor XI deficiency in gynecologic and obstetric patients. *Obstet Gynecol* 68(1): 130-133.
- [14]. Martlew VJ (2000) Peri-operative management of patients with coagulation disorders. *Br J Anaesth* 85(3): 446-455.
- [15]. Duga S, Salomon O (2009) Factor XI deficiency. *Semin Thromb Hemost* 35(4): 416-425.
- [16]. ROTEM® Analysis: Thromboelastometry. <http://www.rotem.de/en/methodology/rotem-analysis/>.
- [17]. ROTEM® Result Interpretation. <http://www.rotem.de/en/methodology/result-interpretation/>.
- [18]. Whiting D, Dinardo JA (2014) TEG and ROTEM: Technology and clinical applications. *Am J Hematol* 89(2): 228-232.
- [19]. Hincker A, Feit J, Sladen RN, Wagener G (2014) Rotational thromboelastometry predicts thromboembolic complications after major non-cardiac surgery. *Crit Care* 18(5): 549.
- [20]. Dekker SE, Viersen VA, Duvekot A, de Jong M, van den Brom CE, et al. (2014) Lysis Onset Time as Diagnostic Rotational Thromboelastometry Parameter for Fast Detection of Hyperfibrinolysis. *Anesthesiology* 121(1): 89-97.
- [21]. Young A, Chapman O, Connor C, Poole C, Rose P, et al. (2012) Thrombosis and cancer. *Nat Rev Clin Oncol* 9(8): 437-449.
- [22]. Goodnough LT, Levy JH, Murphy MF (2013) Concepts of blood transfusion in adults. *Lancet* 381(9880): 1845-1854.
- [23]. Lin Y, Saw CL, Hannach B, Goldman M (2012) Transfusion-related acute lung injury prevention measures and their impact at Canadian Blood Services. *Transfusion* 52(3): 567-574.
- [24]. Pandey S, Vyas GN (2012) Adverse Effects of Plasma Transfusion. *Transfusion* 52(Suppl 1): 65S-79S.
- [25]. Young G, Ebbesen LS, Viuff D, Di Paola J, Konkle BA, et al. (2008) Evaluation of thromboelastography for monitoring recombinant activated factor VII ex vivo in haemophilia A and B patients with inhibitors: a multicentre trial. *Blood Coagul Fibrinolysis* 19(4): 276-282.